

# Update on the Porphyrrias

Amy K. Dickey,<sup>1,2</sup> Rebecca Karp Leaf,<sup>2,3</sup>  
and Manisha Balwani<sup>4</sup>

<sup>1</sup>Division of Pulmonary and Critical Care Medicine, Department of Medicine, Massachusetts General Hospital, Boston, Massachusetts, USA; email: adickey@mgh.harvard.edu

<sup>2</sup>Harvard Medical School, Boston, Massachusetts, USA

<sup>3</sup>Division of Hematology and Oncology, Department of Medicine, Massachusetts General Hospital, Boston, Massachusetts, USA; email: rkarp-leaf@mgh.harvard.edu

<sup>4</sup>Department of Genetics and Genomic Sciences, Icahn School of Medicine at Mount Sinai, New York, NY, USA; email: manisha.balwani@mssm.edu

 ANNUAL  
REVIEWS CONNECT

[www.annualreviews.org](http://www.annualreviews.org)

- Download figures
- Navigate cited references
- Keyword search
- Explore related articles
- Share via email or social media

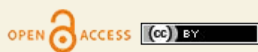Annu. Rev. Med. 2024. 75:321–35

First published as a Review in Advance on  
August 4, 2023

The *Annual Review of Medicine* is online at  
[med.annualreviews.org](http://med.annualreviews.org)

<https://doi.org/10.1146/annurev-med-042921-123602>

Copyright © 2024 by the author(s). This work is licensed under a Creative Commons Attribution 4.0 International License, which permits unrestricted use, distribution, and reproduction in any medium, provided the original author and source are credited. See credit lines of images or other third-party material in this article for license information.



## Keywords

porphyria, acute hepatic porphyria, acute intermittent porphyria, protoporphyria, erythropoietic protoporphyria, porphyria cutanea tarda, congenital erythropoietic porphyria

## Abstract

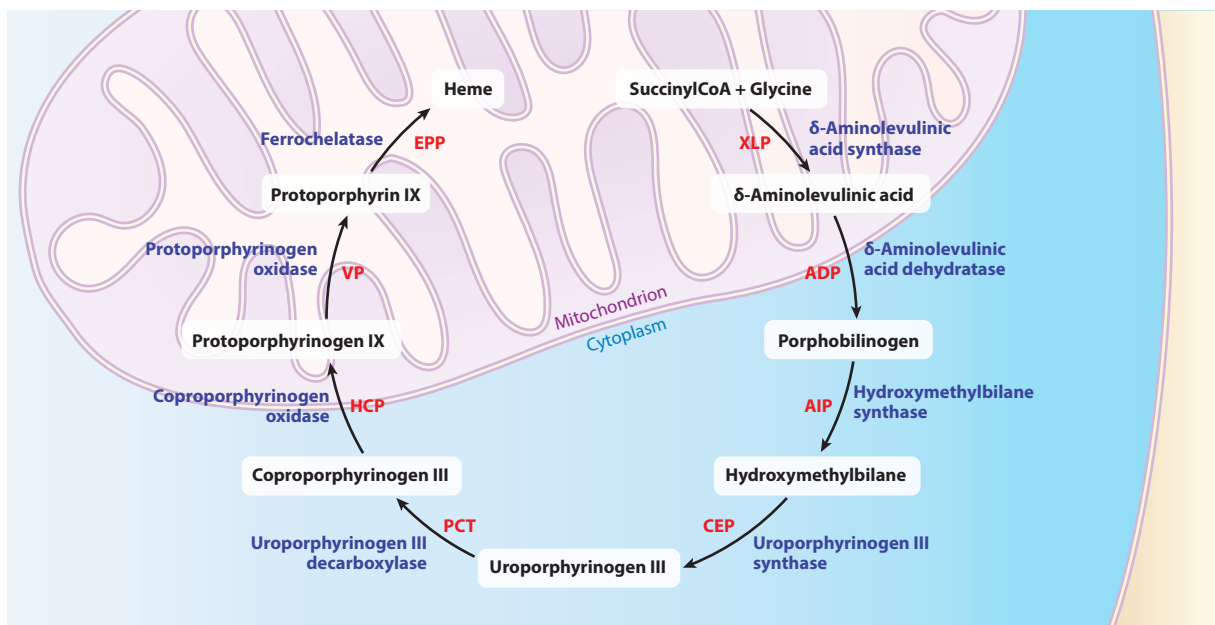
The porphyrias are a group of rare diseases, each resulting from a defect in a different enzymatic step of the heme biosynthetic pathway. They can be broadly divided into two categories, hepatic and erythropoietic porphyrias, depending on the primary site of accumulation of heme intermediates. These disorders are multisystemic with variable symptoms that can be encountered by physicians in any specialty. Here, we review the porphyrias and describe their clinical presentation, diagnosis, and management. We discuss novel therapies that are approved or in development. Early diagnosis is key for the appropriate management and prevention of long-term complications in these rare disorders.

## INTRODUCTION

The porphyrias are a group of rare diseases, each resulting from enzymatic defects of heme synthesis (1). These can be divided into hepatic and erythropoietic porphyrias, depending on the primary site of accumulation of heme intermediates (2). The porphyrias can also be classified clinically as acute hepatic (AHP) and cutaneous, with the latter category being further divided into blistering and nonblistering (3). The eight porphyrias are acute intermittent porphyria (AIP), variegate porphyria (VP), hereditary coproporphyria (HCP),  $\delta$ -aminolevulinic acid dehydratase (ALAD) deficiency porphyria (ADP), erythropoietic protoporphyria (EPP), X-linked protoporphyria (XLP), porphyria cutanea tarda (PCT), and congenital erythropoietic porphyria (CEP) (Figure 1). These are inherited in an autosomal dominant, recessive, or X-linked pattern, except for PCT, which can be sporadic or acquired (2, 4).

In porphyria, decreased or increased enzymatic function results in the accumulation of heme precursors or porphyrins. The specific accumulated intermediates and the site of accumulation are responsible for the distinct clinical features of each type of porphyria (1). Due to variable clinical presentations and decreased awareness of these disorders, long diagnostic delays are common (5). This often leads to chronic complications, significant disease burden, and decreased quality of life (6).

Recent advances in our understanding of the porphyrias have led to the development of novel targeted therapies, dramatically transforming patient care (2). In this review, we aim to discuss the current state of diagnosis and treatment of the acute and cutaneous porphyrias.



**Figure 1**

Heme biosynthesis and porphyria. Abbreviations (clockwise from top right): XLP, X-linked protoporphyria (gain of function in  $\delta$ -aminolevulinic acid synthase 2); ADP,  $\delta$ -aminolevulinic acid dehydratase deficiency porphyria; AIP, acute intermittent porphyria; CEP, congenital erythropoietic porphyria; PCT, porphyria cutanea tarda; HCP, hereditary coproporphyria; VP, variegate porphyria; EPP, erythropoietic protoporphyria.

## ACUTE HEPATIC PORPHYRIA

The AHPs include AIP, VP, HCP, and ADP (7). The first three are inherited in an autosomal dominant fashion with low penetrance, while ADP is an ultrarare recessive disorder. These disorders result from pathogenic genetic variants in hydroxymethylbilane synthase (HMBS), protoporphyrinogen oxidase (PPOX), coproporphyrinogen oxidase (CPOX), and ALAD, respectively. Patients with AHP can develop acute neurovisceral attacks often characterized by abdominal pain, nausea, vomiting, and other neurologic and psychiatric symptoms such as weakness, numbness, paresthesias, seizures, anxiety, depression, or psychosis (7). In VP and HCP, patients may have acute neurovisceral attacks, blistering cutaneous photosensitivity, or both, with cutaneous symptoms occurring more frequently in VP than in HCP (8).

In addition to acute attacks, AHP patients, particularly those with recurrent attacks, can have chronic symptoms and long-term complications such as chronic pain, neuropathy, liver disease, and kidney disease (7).

### Epidemiology and Genetics

Studies suggest that the prevalence of AIP is  $\sim 0.5\text{--}2:100,000$ ; however, analysis of genetic data sets shows that the prevalence of pathogenic variants in HMBS is  $\sim 1:1700$ , suggesting lower penetrance than previously thought (9, 10) (**Table 1**). These data suggest that the penetrance may be  $<1\%$  depending on the degree of underdiagnosis (9). However, the penetrance is 10–20% among family members of symptomatic AIP patients (10–12). VP and HCP are less common, with the prevalence of diagnosed VP being  $\sim 0.3:100,000$  and the prevalence of diagnosed HCP being  $\sim 0.1:100,000$  (10) (**Table 1**). Founder variants exist in Scandinavia for AIP and in South Africa for VP, leading to a higher prevalence of these diseases in those regions (13, 14). ADP is ultrarare, with less than 10 cases reported, all in males (15). Except for ADP, most symptomatic AHP patients are females, as hormones, particularly progesterone, contribute to the onset of attacks and disease activity (10, 16). However, other reasons for differences in disease presentation in individuals with pathogenic variants are poorly understood (9). Misdiagnosis is common, with patients in the United States experiencing an average of 15 years of diagnostic delay (7).

### Pathophysiology

Delta-aminolevulinic acid synthase 1 (ALAS1) is the first and rate-limiting step in heme biosynthesis and is highly inducible. Factors that directly increase ALAS1 transcription or increase heme

**Table 1** Prevalence of the porphyrias

Type of porphyria	Prevalence
Acute intermittent porphyria	$\sim 0.5\text{--}2:100,000$ (9, 10)
Variante porphyria	$\sim 0.3:100,000$ (10)
Hereditary coproporphyrin	$\sim 0.1:100,000$ (10)
ALAD deficiency porphyria	$<10$ cases reported, all in males (15)
Erythropoietic protoporphyria	1:100,000 diagnosed, true prevalence as high as 1:17,000 (10, 42)
X-linked protoporphyria	Up to 10% of protoporphyria (40)
Porphyria cutanea tarda	1:25,000 in the United States (80, 81)
Congenital erythropoietic porphyria	$\sim 1:1,000,000$ , around 200 cases reported worldwide (88)

Abbreviation: ALAD,  $\delta$ -aminolevulinic acid dehydratase.

demand can upregulate ALAS1. With the increase in ALAS1 activity, the enzymatic deficiencies cannot keep up with this increased demand for heme, creating a block in the pathway and leading to the accumulation of porphyrins and porphyrin precursors. The pathogenesis of AHP symptoms is attributed to the accumulation of the toxic metabolites  $\delta$ -aminolevulinic acid (ALA) and porphobilinogen (PBG), particularly ALA (17). Factors that influence the activity of ALAS1 and induce AHP attacks include stress, alcohol, smoking, medications, caloric restriction, acute illnesses, and the luteal phase of the menstrual cycle (17–20). These affect ALAS1 activity either by directly increasing transcription (e.g., dieting or fasting) or increasing hepatic heme demand or consumption (e.g., drugs, illness) (17, 19). Therefore, fasting and heme deficiency can precipitate attacks (17, 19, 21).

## Diagnosis

Clinicians should have a low threshold to screen for AHP, especially in women in the reproductive age group with unexplained, recurrent abdominal pain without a clear etiology or nonspecific neurologic symptoms, including neuropathy and weakness (3, 22). The diagnostic test for AHP includes assessing PBG and ALA in a spot urine sample (22) (**Table 2**). Urine porphyrin levels should not be used in isolation for screening or diagnosis. Significant elevation in urine PBG is highly specific for AHP, but elevations in urine porphyrins are neither specific nor diagnostic (23). Urine porphyrins can be elevated in liver disease, in heavy metal poisoning, and in the setting of the use of a variety of medications (23). Spot testing with normalization to urine creatinine is recommended, and 24-h testing is unnecessary, with the potential to cause delays in diagnosis (22, 24). Although urine PBG and ALA are elevated in attacks of AIP, VP, and HCP, in ADP only urine ALA and porphyrins are elevated due to the underlying enzymatic defect (15).

Testing during acute symptoms is important because the urine PBG may be normal between attacks, leading to the potential for a missed diagnosis (22, 23). Compared with AIP, the urine PBG may be more transiently elevated in VP and HCP. Second-line testing should be pursued if testing for AHP is positive or inconclusive (23). This includes testing urine, fecal, and plasma porphyrins. Stool porphyrins are often elevated in VP and HCP, with stool coproporphyrin being particularly elevated in HCP and stool protoporphyrin and coproporphyrin being particularly elevated in VP (23). Plasma porphyrins may be elevated in AHP, especially in the setting of cutaneous symptoms in VP and HCP. While urine ALA is elevated in acute attacks of porphyria, this is less specific for

**Table 2** Symptoms and key diagnostic testing for the porphyrias

Type of porphyria	Symptoms	Key diagnostic test
<i>Acute hepatic</i>		
AIP, VP, HCP, ADP	Acute pain attacks and/or other neurovisceral symptoms, blistering lesions on sun-exposed skin (VP, HCP)	Urine PBG <sup>a</sup> and ALA <sup>b</sup>
<i>Cutaneous</i>		
Blistering (PCT, CEP, VP, HCP)	Blistering lesions on sun-exposed skin	Plasma and urine porphyrins <sup>a</sup>
Nonblistering (EPP, XLP)	Painful light sensitivity that is typically nonblistering	Erythrocyte protoporphyrin <sup>c</sup>

Abbreviations: ADP,  $\delta$ -aminolevulinic acid dehydratase deficiency porphyria; AIP, acute intermittent porphyria; ALA, aminolevulinic acid; CEP, congenital erythropoietic porphyria; EPP, erythropoietic protoporphyria; HCP, hereditary coproporphyria; PBG, porphobilinogen; PCT, porphyria cutanea tarda; VP, variegate porphyria; XLP, X-linked protoporphyria.

<sup>a</sup>Random spot urine samples are recommended over 24-h values; however, concurrent urine creatinine must also be collected.

<sup>b</sup>Urine PBG may not be elevated in ADP, though ALA will be markedly elevated.

<sup>c</sup>Including total protoporphyrin and quantification of metal-free and zinc fractions.

AHP than PBG elevation. For patients with AIP, the measurement of HMBS has been used in the past; however, the expected activity ranges for individuals with and without AIP have overlapping values, decreasing the usefulness of this test (23). Genetic testing is useful to confirm the diagnosis, determine the subtype of porphyria, and test at-risk family members. Genetic testing is available clinically as part of multigene panels.

## Natural History

Patients with acute porphyria may develop autonomic neuropathy, peripheral neuropathy, and/or central nervous system dysfunction (25). The autonomic neuropathy in AHP causes diffuse, severe abdominal pain, tachycardia, hypertension, constipation, nausea, and vomiting. Peripheral neuropathy can be profound and progressive, resulting in paresthesias and/or weakness, including respiratory muscle weakness. The central nervous system dysfunction leads to insomnia, anxiety, depression, hallucinations, cognitive dysfunction, and/or seizures. Other common symptoms during attacks include hyponatremia, dark or red urine, and fatigue (18–20). The most common of these symptoms are abdominal pain, fatigue, nausea, dark or red urine, and weakness (18, 24).

Studies show that about 60% of symptomatic patients with AIP will develop chronic kidney disease, and the risk is lower in patients with elevated porphyrin precursors without overt clinical symptoms compared to those with symptoms. AHP patients are also at risk of liver disease and hepatocellular carcinoma (HCC) (18, 26, 27). The risk of HCC increases with age, and it typically occurs in noncirrhotic livers (28). Studies from Europe suggest an annual incidence of 1.8% in AHP patients who have had previous elevations of urine PBG (29). A US study found HCC in 1.5% of AHP patients including asymptomatic carriers (28).

The disease severity and pattern of symptoms in AHP vary widely among patients. A vast majority of HMBS pathogenic variant carriers will remain latent with no clinical symptoms and normal biochemical testing (9, 11, 12). Asymptomatic high excretors are defined as patients with no history of recent acute attacks but with elevations in urine PBG  $\sim$ 4 times the upper limit of normal. Some patients have one or a few attacks throughout their lifetime, classified as sporadic attacks (18). A subset of patients have recurrent attacks ( $\geq$ 4 per year) and also report chronic symptoms between attacks (6). Survey studies reveal remarkable impairments in quality of life, which are similar for those with and without recurrent attacks (6).

## Clinical Management

The management of symptoms should focus on avoiding triggering or precipitating factors (22). Patients should be counseled extensively on the use of safe medications and the avoidance of unsafe medications, fasting, dieting, alcohol, tobacco, and other factors that may precipitate symptoms (22).

**Management of acute attacks.** Acute attacks that require hospitalization should be treated with intravenous hemin (21, 30) (**Table 3**). Ideally, an elevated urine PBG level should be determined before hemin administration, but patients with a confirmed AHP diagnosis should receive hemin based on their symptoms, as waiting for results may lead to delays in therapy. Hemin mixed in 25% albumin rather than sterile water is more stable and less likely to cause phlebitis (31). Typically, patients receive 3–4 mg/kg daily over 4 days, a regimen that decreases symptoms and urine PBG, although neurologic improvement may lag (21, 24). Hemin works by repleting the free heme pool in the liver, which downregulates ALAS1 and thereby decreases the production of the neurotoxic heme precursors ALA and PBG (31). Intravenous dextrose may also prove useful in downregulating ALAS1 (22, 24). Pain should be managed aggressively with analgesics, and patients may require antiemetics for nausea. Hypertension, tachycardia, and hyponatremia are common,

**Table 3 Available therapies and therapies under development for porphyria**

Type of porphyria	Therapies in use <sup>a</sup>	Potential therapies in clinical trials	Therapies in development
<i>Acute hepatic</i>			
AIP	Panhematin (21), givosiran (37)	None	Gene therapy (93), intravenous administration of PBGD mRNA (94)
VP	Panhematin (21) <sup>b</sup> , givosiran (37)	None	None
HCP	Panhematin (21, 30) <sup>b</sup> , givosiran (37)	None	None
ADP	Panhematin (21, 95) <sup>b,c</sup>	None	None
<i>Blistering cutaneous</i>			
PCT	Therapeutic phlebotomy (86), hydroxychloroquine (85), hepatitis C antiviral therapy (87)	None	None
CEP	Blood transfusion (88), therapeutic phlebotomy (90), iron chelation (96)	None	Ciclopirox (92)
<i>Nonblistering cutaneous</i>			
EPP	Afamelanotide (55)	Dersimelagon (59), bitopertin (60), cimetidine (61)	Antisense oligonucleotides (97), inhibition of ABCG2 transporter (98)
XLP	Afamelanotide (55)	Dersimelagon (59), cimetidine (61)	None

Abbreviations: ADP, δ-aminolevulinic acid dehydratase deficiency porphyria; AIP, acute intermittent porphyria; ALA, aminolevulinic acid; CEP, congenital erythropoietic porphyria; EPP, erythropoietic protoporphyria; HCP, hereditary coproporphyria; PBGD, porphobilinogen deaminase; PCT, porphyria cutanea tarda; VP, variegate porphyria; XLP, X-linked protoporphyria.

<sup>a</sup>For details on liver and bone marrow transplant in the porphyrias, please see text.

<sup>b</sup>Panhematin is not approved for treatment of VP, HCP, or ADP but is used off-label.

<sup>c</sup>In case reports, givosiran has not been shown to be beneficial in ADP (99).

and electrolytes should be carefully monitored and repleted. Patients should be monitored for neurologic complications, including seizures.

**Prevention of attacks.** Hemin has been used prophylactically off-label in AHP patients with recurrent attacks to prevent attacks and hospitalization (32). Long-term hemin use can be associated with complications, including iron overload and phlebitis. Other therapies, including GnRH (gonadotropin-releasing hormone) analogs, have been used in women with cyclic attacks related to their menstrual cycle, with mixed results (33). While liver transplantation is curative in AHP, this is generally only considered in individuals with severely debilitating symptoms not responsive to other pharmacologic measures (34, 35). Both liver and kidney transplantation have been reported in AHP cases with end-stage renal disease. In a report from France, kidney transplantation in patients with AIP and end-stage renal disease significantly reduced AIP disease activity (36).

Givosiran, a small interfering RNA (siRNA) targeting ALAS1 in hepatocytes, is approved by the US Food and Drug Administration for treating adults with AHP (Table 3). It is administered subcutaneously at 2.5 mg/kg monthly to prevent attacks. In a pivotal phase III clinical trial, givosiran decreased the annualized attack rate by 74% compared to the placebo group (37). It was associated with reduced urine ALA and PBG and improved quality of life. Patients on givosiran experienced an improvement in chronic symptoms and a decrease in hemin and pain medication

usage. The side effects include increased liver biochemistries, decreased eGFR (estimated glomerular filtration rate), and increased homocysteine levels (37, 38). Patients on givosiran should be monitored closely after treatment initiation with clinical and laboratory assessments, including the measurement of liver enzymes, kidney function, homocysteine, amylase, and lipase (27). Givosiran should not be used in women who are pregnant or planning to become pregnant, as limited safety data exist.

No therapies are known to treat the blistering photosensitivity seen in VP and HCP, besides sunlight avoidance and sun-protective clothing. Givosiran's role in treating the skin symptoms of VP and HCP is unclear.

**Long-term monitoring.** Patients should be monitored annually with assessments of hepatic and kidney function (27). In patients with persistent liver enzyme elevations, other etiologies should be considered and ruled out. Up to 59% of symptomatic AIP cases have porphyria-associated kidney disease (22). In AHP patients with porphyria-associated kidney disease and concomitant chronic hypertension, medical management and monitoring are important to prevent additional kidney damage (22). AHP patients over age 50 should have surveillance by liver ultrasounds every 6 months, regardless of clinical symptoms, to monitor for HCC (27).

## ERYTHROPOIETIC PROTOPORPHYRIA AND X-LINKED PORPHYRIA

EPP and XLP are rare photodermatoses characterized by severe painful cutaneous phototoxicity after light exposure. Patients with EPP have pathogenic variants of ferrochelatase (*FECH*), the last enzyme of heme synthesis. EPP is recessive, and more than 95% of patients have a pathogenic variant on one allele and a common *FECH c.315-48T>C* low-expression variant on the other (39–41). The *FECH c.315-48T>C* variant has a prevalence of 10% in the Caucasian population and around 50% in East Asians (42).

Up to 10% of individuals with protoporphyria will be found to have XLP upon molecular testing (40). While EPP is caused by loss-of-function variants in *FECH*, patients with XLP have gain-of-function pathogenic variants in the erythroid-specific *ALAS2*, which encodes the first enzyme of heme synthesis (43, 44). Females with XLP may present with a clinically variable phenotype ranging from asymptomatic to equally symptomatic as males based on X chromosome inactivation (43, 44). Protoporphyria due to a pathogenic variant of another gene, *CfpX*, has been identified in one family (45). In about 4% of cases with the protoporphyria phenotype, no pathogenic variants have been identified in these genes. The prevalence of protoporphyria was previously thought to be about 1:100,000; however, analysis of genetic data sets suggests that EPP may be as common as 1:17,000 due to underdiagnosis (10, 42) (Table 1).

## Diagnosis

In both EPP and XLP, total erythrocyte protoporphyrin that is predominantly metal-free accumulates in erythroid cells and secondarily in the plasma and bile (46). Due to the deficiency of *FECH*, which inserts iron into the protoporphyrin IX tetrapyrrole to form heme, the percentage of protoporphyrin that is metal-free in EPP is >85%, with the remainder being complexed to zinc (40). In XLP, on the other hand, the zinc fraction is typically 50–85% (40, 43). Protoporphyria is diagnosed by a measurement of total erythrocyte protoporphyrin that is more than 3–4 times normal and predominantly metal-free (47) (Table 2). Notably, many laboratories offer a “free erythrocyte protoporphyrin” (“FEP”) test that only measures zinc erythrocyte protoporphyrin, and use of such testing could miss a diagnosis of protoporphyria, as zinc erythrocyte protoporphyrin may be normal in protoporphyria (46). The United Porphyrias Association and the European Porphyria Network websites provide lists of acceptable laboratories for protoporphyria testing. Genetic

testing is useful both to confirm the diagnosis and to differentiate between EPP and XLP. Because ~4% of patients with protoporphyria have cryptic or unknown variants, negative genetic testing does not rule out the disease (40, 47). While plasma porphyrins are often elevated in protoporphyria, plasma, stool, and urine porphyrins may all be normal, so these should not be used to establish a diagnosis (48).

### Clinical Presentation

Phototoxic symptoms in EPP and XLP are indistinguishable. In both, protoporphyrin absorbs energy from light and damages the endothelium and subcutaneous tissues through a process that involves the production of reactive oxygen species (49, 50). After light exposure, patients experience a prodrome of tingling and itching that can progress to severe burning pain and allodynia, which can last for days (51, 52). Pain is often associated with nonpitting edema and sometimes petechiae, and the most sensitive skin regions are the hands, face, and feet (51).

Because patients are sensitive to the blue region of visible light and not primary UV light, broad-spectrum or tinted sunscreen might have a small benefit, but other sunscreens are ineffective (47). Light avoidance and light-protective clothing are needed to prevent symptoms, which impair quality of life (53, 54). Afamelanotide was approved in the United States in 2019 to prevent phototoxic symptoms in protoporphyria (55–58) (**Table 3**). It is an  $\alpha$ -melanocyte stimulating hormone ( $\alpha$ -MSH) agonist administered as a subcutaneous implant every 2 months. This medication increases eumelanin and decreases light-mediated protoporphyrin activation through its antioxidant effect (58).

Clinical trials are underway for new therapies for protoporphyria (59, 60) (**Table 3**). These include dersimelagon, an orally administered small-peptide  $\alpha$ -MSH agonist currently in a phase III extension study (59). In a phase II clinical trial, dersimelagon-treated patients had a clinically significant increase in the time to first prodromal symptoms compared to placebo. Additionally, a phase II clinical trial is underway for bitopertin, which is a potential disease-modifying therapy that inhibits the uptake of glycine into erythroid cells (60). A phase II clinical trial for cimetidine for protoporphyria is also ongoing (61).

### Anemia and Iron Deficiency

Patients with protoporphyria have an increased risk of anemia and iron deficiency, which is poorly understood (62–67). Soluble transferrin receptor levels in protoporphyria patients suggest that hematopoiesis in protoporphyria may not truly be iron restricted, and supplementing iron has been observed to increase protoporphyrin in EPP patients, at least transiently (64, 65, 68–70). Current recommendations are to consider supplemental iron in EPP patients who are symptomatic and/or have both hemoglobin <10 g/dL and ferritin <10  $\mu$ g/L (47). Because supplemental iron in the setting of normal FECH activity is thought to be beneficial to potential heme formation, iron supplementation for iron deficiency in XLP is recommended (47, 71). Due to the risk of anemia in protoporphyria, hemoglobin and iron studies should be monitored at least yearly (47).

### Liver Dysfunction

Because protoporphyrin is hydrophobic, it is excreted in the bile of protoporphyria patients—not in the urine, as in other porphyrias. This can lead to liver dysfunction in a subset of protoporphyria patients. While ~27% of patients may have elevated liver biochemistries, approximately 2–4% develop liver failure due to the toxic effects of protoporphyrin on the liver (72). Protoporphyrin hepatopathy is characterized by protoporphyrin deposition in the liver, particularly the characteristic Maltese-cross inclusions visible with polarized light (73, 74). In the context of liver failure



in protoporphyria, protoporphyrin levels can rise substantially, potentiating damage to the liver (73). Therapies such as plasmapheresis may be able to temporize the protoporphyrin-mediated liver damage, but progression to liver failure and liver transplantation are expected (75, 76). In protoporphyria, bone marrow transplantation is curative and is typically performed after liver transplantation to prevent recurrence in the transplanted liver (77, 78). Patients with protoporphyria and progressive protoporphyric hepatopathy should be cared for by a hepatologist with experience in managing protoporphyria-related liver disease and at a liver transplant center (47).

Total erythrocyte protoporphyrin levels, plasma porphyrin levels, and liver biochemistries should be monitored at least yearly, and a hepatologist should evaluate any abnormalities in liver biochemistries (47). Patients should be vaccinated against hepatitis A and B and advised to avoid excessive alcohol intake (79).

## PORPHYRIA CUTANEA TARDA

PCT is thought to be the most common type of porphyria, with an estimated prevalence of 1:25,000 in the United States (80, 81) (**Table 1**). While variants of uroporphyrinogen decarboxylase (*UROD*), found in 17% of US patients, can predispose to disease, there are many other risk factors (4, 82). Variants in *UROD* are neither necessary nor sufficient for developing PCT. Therefore, while the other types of porphyria are inherited, PCT is considered an acquired condition.

Besides pathogenic variants of *UROD*, other risk factors for PCT include viral hepatitis, alcohol consumption, tobacco use, estrogen use, hemochromatosis, and HIV (4). In the United States, these risk factors are found in 69%, 87%, 81%, 66%, 53%, and 13% of patients, respectively; however, the prevalence of risk factors among PCT patients varies highly by country (82). Most patients with PCT will have at least two risk factors, which collectively decrease patients' hepatic *UROD* activity to <50% (80, 82). The end result is an increase in hepatic iron, which produces functional inhibition of the *UROD* enzyme, possibly through the production of an oxidized porphyrin that inhibits *UROD* (83).

In PCT, the accumulated porphyrins are photoactivated by light, producing skin fragility and blistering (82). Patients may also develop hypertrichosis and scarring. However, unlike in protoporphyria, skin symptoms in PCT are often not painful (51, 81, 82). The cutaneous signs and symptoms in VP and HCP and late-onset CEP can be identical to PCT (81, 84).

PCT is diagnosed by urine or plasma porphyrins (**Table 2**). Either will demonstrate marked elevations of porphyrins that are many-fold normal, and elevations of uroporphyrin are especially prominent (80, 81). Risk factors such as *UROD* variants, variants consistent with hemochromatosis, use of estrogens, smoking, alcohol, and positive HIV status should also be assessed during the work-up. While a skin biopsy can support the diagnosis of PCT, this is not sufficient for diagnosis, as identical pathology can be observed in pseudoporphyria, which can be idiopathic or due to various medications (81, 82). PCT can be distinguished from the cutaneous symptoms of variegate porphyria and hereditary coproporphyria through genetic testing (48, 81). Moreover, PCT can be distinguished from late-onset congenital erythropoietic porphyria through genetic testing or the measurement of erythrocyte porphyrins, which are elevated in CEP but not PCT (84).

PCT can be effectively treated with phlebotomy or low-dose hydroxychloroquine (85, 86) (**Table 3**). Phlebotomy decreases serum porphyrins and reduces iron overload by removing blood from the body, while low-dose hydroxychloroquine promotes the excretion of porphyrins through the urine. In PCT patients with hepatitis C, PCT can be effectively treated by addressing hepatitis C alone using direct-acting antivirals (87). Urine porphyrins, plasma porphyrins, ferritin, iron studies, and complete blood count should be monitored during therapy, and urine porphyrins and plasma porphyrins should be measured at least yearly thereafter to monitor for recurrence.

## CONGENITAL ERYTHROPOIETIC PORPHYRIA

CEP is a rare type of porphyria with an estimated prevalence of 1:1,000,000, with ~200 cases reported total worldwide (88) (**Table 1**). CEP is recessively inherited, with patients possessing two pathogenic variants of uroporphyrinogen synthase (88). It has also been described in one patient with a pathogenic variant of a GATA-1 erythrocyte-specific transcription factor on the X chromosome (89). CEP results in the accumulation of porphyrins in erythrocytes. This produces blistering and skin fragility beginning in infancy, which can be highly disfiguring and can result in auto-amputation (88). Patients may have fluorescent erythrodontia, red fluorescent urine, corneal ulcers, thrombocytopenia, and transfusion-dependent anemia (88). For those who are not anemic, phlebotomy can help decrease erythrocyte porphyrins and minimize symptoms (90) (**Table 3**). There may also be a role for iron chelation therapy in CEP (91) (**Table 3**). Bone marrow transplantation is curative in CEP and is beneficial for those who are transfusion dependent or who have disfiguring symptoms (88). The disease severity can vary greatly, ranging from hydrops fetalis to adult-onset forms restricted to mild cutaneous photosensitivity (84, 88). Outside of phlebotomy, iron chelation, and bone marrow transplantation, the management of cutaneous symptoms in CEP currently centers on sunlight avoidance and sun-protective clothing. A clinical trial for CEP is planned to test the efficacy of ciclopirox, which has been shown to stabilize the uroporphyrinogen synthase enzyme (92) (**Table 3**).

## CONCLUSION

The porphyrias are a diverse group of rare diseases characterized by alterations in the heme biosynthetic pathway. They are multisystemic disorders, and physicians of essentially every specialty have the potential to encounter these patients. While more research is needed to better understand the pathophysiology of the porphyrias and to develop effective disease-modifying treatments, the currently approved therapies and those in clinical development provide great hope to the porphyria community.

## DISCLOSURE STATEMENT

Dr. Dickey is a consultant for Alnylam Pharma and Recordati Pharma and has received grant support from Disc Medicine for a separate research study. Dr. Leaf has received consulting fees from Mitsubishi Tanabe Pharma, Alnylam Pharma, and Recordati Pharma. Dr. Balwani received clinical trial support from Alnylam, Disc Medicine, and Mitsubishi Tanabe and has consulted for Alnylam, Recordati Rare Diseases, Mitsubishi Tanabe, and Disc Medicine.

## ACKNOWLEDGMENTS

Dr. Dickey receives funding from National Institute of Arthritis and Musculoskeletal and Skin Diseases grant 1K23AR079586. All authors are members of the Porphyrias Consortium (PC). PC is part of the Rare Diseases Clinical Research Network, which is funded by the National Institutes of Health and led by the National Center for Advancing Translational Sciences (NCATS) through its Division of Rare Diseases Research Innovation. PC is funded under grant number U54DK083909 as a collaboration between NCATS and the National Institute of Diabetes and Digestive and Kidney Diseases. We thank Grace Lassiter, MD, for designing **Figure 1**.

## LITERATURE CITED

1. Bissell DM, Anderson KE, Bonkovsky HL. 2017. Porphyria. *N. Engl. J. Med.* 377(9):862–72
2. Manceau H, Gouya L, Puy H. 2017. Acute hepatic and erythropoietic porphyrias: from ALA synthases 1 and 2 to new molecular bases and treatments. *Curr. Opin. Hematol.* 24(3):198–207

3. Lefever S, Peersman N, Meersseman W, et al. 2022. Development and validation of diagnostic algorithms for the laboratory diagnosis of porphyrias. *J. Inherit. Metab. Dis.* 45(6):1151–62
4. Bulaj ZJ, Phillips JD, Ajioka RS, et al. 2000. Hemochromatosis genes and other factors contributing to the pathogenesis of porphyria cutanea tarda. *Blood* 95(5):1565–71
5. Lala SM, Naik H, Balwani M. 2018. Diagnostic delay in erythropoietic protoporphyria. *J. Pediatr.* 202:320–23.e2
6. Dickey A, Wheeden K, Lyon D, et al. 2022. Quantifying the impact of symptomatic acute hepatic porphyria on well-being via patient-reported outcomes: results from the Porphyria Worldwide Patient Experience Research (POWER) study. *JIMD Rep.* 64(1):104–13
7. Bonkovsky HL, Maddukuri VC, Yazici C, et al. 2014. Acute porphyrias in the USA: features of 108 subjects from porphyrias consortium. *Am. J. Med.* 127(12):1233–41
8. Karim Z, Lyoumi S, Nicolas G, et al. 2015. Porphyrias: a 2015 update. *Clin. Res. Hepatol. Gastroenterol.* 39(4):412–25
9. Chen B, Solis-Villa C, Hakenberg J, et al. 2016. Acute intermittent porphyria: predicted pathogenicity of HMBS variants indicates extremely low penetrance of the autosomal dominant disease. *Hum. Mutat.* 37(11):1215–22
10. Elder G, Harper P, Badminton M, et al. 2013. The incidence of inherited porphyrias in Europe. *J. Inherit. Metab. Dis.* 36(5):849–57
11. Lamon JM, Frykholm BC, Tschudy DP. 1979. Family evaluations in acute intermittent porphyria using red cell uroporphyrinogen I synthetase. *J. Med. Genet.* 16(2):134–39
12. von und zu Fraunberg M, Pischik E, Udd L, et al. 2005. Clinical and biochemical characteristics and genotype-phenotype correlation in 143 Finnish and Russian patients with acute intermittent porphyria. *Medicine* 84(1):35–47
13. Floderus Y, Shoolingin-Jordan PM, Harper P. 2002. Acute intermittent porphyria in Sweden. Molecular, functional and clinical consequences of some new mutations found in the porphobilinogen deaminase gene. *Clin. Genet.* 62(4):288–97
14. Hift RJ, Peters TJ, Meissner PN. 2012. A review of the clinical presentation, natural history and inheritance of variegate porphyria: its implausibility as the source of the “Royal Malady.” *J. Clin. Pathol.* 65(3):200–5
15. Lahiji AP, Anderson KE, Chan A, et al. 2020. 5-Aminolevulinic acid synthase induction and long-term response to hemin. *Mol. Genet. Metab.* 131(4):418–23
16. Andersson C, Innala E, Bäckström T. 2003. Acute intermittent porphyria in women: clinical expression, use and experience of exogenous sex hormones. A population-based study in northern Sweden. *J. Intern. Med.* 254(2):176–83
17. Jericó D, Córdoba KM, Sampedro A, et al. 2022. Recent insights into the pathogenesis of acute porphyria attacks and increasing hepatic PBGD as an etiological treatment. *Life* 12(11):1858
18. Storjord E, Dahl JA, Landsem A, et al. 2018. Lifestyle factors including diet and biochemical biomarkers in acute intermittent porphyria: results from a case-control study in northern Norway. *Mol. Genet. Metab.* 128(3):254–70
19. Handschin C, Lin J, Rhee J, et al. 2005. Nutritional regulation of hepatic heme biosynthesis and porphyria through PGC-1 $\alpha$ . *Cell* 122(4):505–15
20. Podvinec M, Handschin C, Looser R, et al. 2004. Identification of the xenosensors regulating human 5-aminolevulinic acid synthase. *PNAS* 101(24):9127–32
21. Herrick AL, Moore MR, Mccoll KEL, et al. 1989. Controlled trial of haem arginate in acute hepatic porphyria. *Lancet* 1(8650):1295–97
22. Balwani M, Wang B, Anderson KE, et al. 2017. Acute hepatic porphyrias: recommendations for evaluation and long-term management. *Hepatology* 66(4):1314–22
23. Anderson KE, Lobo R, Salazar D, et al. 2021. Biochemical diagnosis of acute hepatic porphyria: updated expert recommendations for primary care physicians. *Am. J. Med. Sci.* 362(2):113–21
24. Anderson KE, Bloomer JR, Bonkovsky HL, et al. 2005. Recommendations for the diagnosis and treatment of the acute porphyrias. *Ann. Intern. Med.* 142(6):439–50

25. Simon NG, Herkes GK. 2011. The neurologic manifestations of the acute porphyrias. *J. Clin. Neurosci.* 18(9):1147–53
26. Storjord E, Airila-Månsson S, Karlsen K, et al. 2022. Dental and periodontal health in acute intermittent porphyria. *Life* 12(8):1270
27. Wang B, Bonkovsky HL, Lim JK, et al. 2023. AGA clinical practice update on diagnosis and management of acute hepatic porphyrias: expert review. *Gastroenterology* 164(3):484–91
28. Saberi B, Naik H, Overbey JR, et al. 2021. Hepatocellular carcinoma in acute hepatic porphyrias: results from the longitudinal study of the U.S. Porphyrias Consortium. *Hepatology* 73(5):1736–46
29. Lissing M, Vassiliou D, Floderus Y, et al. 2022. Risk of primary liver cancer in acute hepatic porphyria patients: a matched cohort study of 1244 individuals. *J. Intern. Med.* 291(6):824–36
30. Ma E, Mar V, Varigos G, et al. 2011. Haem arginate as effective maintenance therapy for hereditary coproporphyria. *Australas. J. Dermatol.* 52(2):135–38
31. Bonkovsky HL, Healey JF, Lourie AN, et al. 1991. Intravenous heme-albumin in acute intermittent porphyria: evidence for repletion of hepatic hemoproteins and regulatory heme pools. *Am. J. Gastroenterol.* 86(8):1050–56
32. Marsden JT, Guppy S, Stein P, et al. 2015. Audit of the use of regular haem arginate infusions in patients with acute porphyria to prevent recurrent symptoms. *JIMD Rep.* 22:57–65
33. Schulenburg-Brand D, Gardiner T, Guppy S, et al. 2017. An audit of the use of gonadorelin analogues to prevent recurrent acute symptoms in patients with acute porphyria in the United Kingdom. *JIMD Rep.* 36:99–107
34. Thunell S, Henrichson A, Floderus Y, et al. 1992. Liver transplantation in a boy with acute porphyria due to aminolaevulinatase deficiency. *Eur. J. Clin. Chem. Clin. Biochem.* 30(10):599–606
35. Stojeba N, Meyer C, Jeanpierre C, et al. 2004. Recovery from a variegate porphyria by a liver transplantation. *Liver Transpl.* 10(7):935–38
36. Lazareth H, Talbi N, Kamar N, et al. 2020. Kidney transplantation improves the clinical outcomes of acute intermittent porphyria. *Mol. Genet. Metab.* 131(1–2):259–66
37. Balwani M, Sardh E, Ventura P, et al. 2020. Phase 3 trial of RNAi therapeutic givosiran for acute intermittent porphyria. *N. Engl. J. Med.* 382(24):2289–301
38. Ventura P, Sardh E, Longo N, et al. 2022. Hyperhomocysteinemia in acute hepatic porphyria (AHP) and implications for treatment with givosiran. *Expert Rev. Gastroenterol. Hepatol.* 16(9):879–94
39. Whatley SD, Mason NG, Holme SA, et al. 2010. Molecular epidemiology of erythropoietic protoporphyria in the U.K. *Br. J. Dermatol.* 162(3):642–46
40. Balwani M, Doheny D, Bishop DF, et al. 2013. Loss-of-function ferrochelatase and gain-of-function erythroid-specific 5-aminolevulinatase mutations causing erythropoietic protoporphyria and X-linked protoporphyria in North American patients reveal novel mutations and a high prevalence of X-linked protoporphyria. *Mol. Med.* 19(1):26–29
41. Whatley SD, Mason NG, Holme SA, et al. 2007. Gene dosage analysis identifies large deletions of the *FECH* gene in 10% of families with erythropoietic protoporphyria. *J. Invest. Dermatol.* 127:2790–94
42. Dickey AK, Quick C, Ducamp S, et al. 2020. Evidence in the UK Biobank for the underdiagnosis of erythropoietic protoporphyria. *Genet. Med.* 23(1):140–48
43. Whatley SD, Ducamp S, Gouya L, et al. 2008. C-terminal deletions in the *ALAS2* gene lead to gain of function and cause X-linked dominant protoporphyria without anemia or iron overload. *Am. J. Hum. Genet.* 83(3):408–14
44. Ducamp S, Schneider-Yin X, de Rooij F, et al. 2013. Molecular and functional analysis of the C-terminal region of human erythroid-specific 5-aminolevulinic synthase associated with X-linked dominant protoporphyria (XLDPP). *Hum. Mol. Genet.* 22(7):1280–88
45. Yien YY, Ducamp S, van der Vorm LN, et al. 2017. Mutation in human CLPX elevates levels of  $\delta$ -aminolevulinatase synthase and protoporphyrin IX to promote erythropoietic protoporphyria. *PNAS* 114(38):E8045–52
46. Gou EW, Balwani M, Bissell DM, et al. 2015. Pitfalls in erythrocyte protoporphyrin measurement for diagnosis and monitoring of protoporphyrias. *Clin. Chem.* 61(12):1453–56

47. Dickey AK, Naik H, Keel SB, et al. 2023. Evidence-based consensus guidelines for the diagnosis and management of erythropoietic protoporphyria and X-linked protoporphyria. *J. Am. Acad. Dermatol.* 89(6):1227–37
48. Hindmarsh JT, Oliveras L, Greenway DC. 1999. Biochemical differentiation of the porphyrias. *Clin. Biochem.* 32(8):609–19
49. Lim HW. 1989. Mechanisms of phototoxicity in porphyria cutanea tarda and erythropoietic protoporphyria. *Immunol. Ser.* 46:671–85
50. Timonen K, Kariniemi AL, Niemi KM, et al. 2000. Vascular changes in erythropoietic protoporphyria: histopathologic and immunohistochemical study. *J. Am. Acad. Dermatol.* 43(3):489–97
51. Raef HS, Rebeiz L, Leaf RK, et al. 2023. Light-related cutaneous symptoms of erythropoietic protoporphyria and associations with light sensitivity measurements. *JAMA Dermatol.* 159(2):204–8
52. Dickey A, Rebeiz L, Raef H, et al. 2022. Prospective observational pilot study of quantitative light dosimetry in erythropoietic protoporphyria. *J. Am. Acad. Dermatol.* 88(5):1148–51
53. Naik H, Overbey JR, Desnick RJ, et al. 2019. Evaluating quality of life tools in North American patients with erythropoietic protoporphyria and X-linked protoporphyria. *JIMD Rep.* 50(1):9–19
54. Dickey A. 2019. Pitfalls and proposed solutions for patient communication about erythropoietic protoporphyria: a survey of parents and adult patients. *J. Am. Acad. Dermatol.* 81(5):1204–7
55. Langendonk JG, Balwani M, Anderson KE, et al. 2015. Afamelanotide for erythropoietic protoporphyria. *N. Engl. J. Med.* 373(1):48–59
56. Biolcati G, Marchesini E, Sorge F, et al. 2015. Long-term observational study of afamelanotide in 115 patients with erythropoietic protoporphyria. *Br. J. Dermatol.* 172(6):1601–12
57. Wensink D, Wagenmakers MAEM, Barman-Aksözen J, et al. 2020. Association of afamelanotide with improved outcomes in patients with erythropoietic protoporphyria in clinical practice. *JAMA Dermatol.* 156(5):570–75
58. Barman-Aksözen J, Nydegger M, Schneider-Yin X, et al. 2020. Increased phototoxic burn tolerance time and quality of life in patients with erythropoietic protoporphyria treated with afamelanotide—a three years observational study. *Orphanet J. Rare Dis.* 15(2):213
59. Balwani M, Bonkovsky HL, Belongie KJ, et al. 2020. Erythropoietic protoporphyria: phase 2 clinical trial results evaluating the safety and effectiveness of dersimelagon (MT-7117), an oral MC1R agonist. *Blood* 136(Suppl. 1):51
60. Halloy F, Iyer PS, Ghidini A, et al. 2021. Repurposing of glycine transport inhibitors for the treatment of erythropoietic protoporphyria. *Cell Chem. Biol.* 28(8):1221–34.e6
61. Heerfordt IM, Lerche CM, Wulf HC. 2022. Cimetidine for erythropoietic protoporphyria. *Photodiagnos. Photodyn. Ther.* 38:102793
62. Barman-Aksözen J, Halloy F, Iyer PS, et al. 2019. Delta-aminolevulinic acid synthase 2 expression in combination with iron as modifiers of disease severity in erythropoietic protoporphyria. *Mol. Genet. Metab.* 128(3):304–8
63. Holme SA, Worwood M, Anstey AV, et al. 2007. Erythropoiesis and iron metabolism in dominant erythropoietic protoporphyria. *Blood* 110(12):4108–10
64. Bossi K, Lee J, Schmeltzer P, et al. 2015. Homeostasis of iron and hepcidin in erythropoietic protoporphyria. *Eur. J. Clin. Investig.* 45(10):1032–41
65. Barman-Aksözen J, Girelli D, Aurizi C, et al. 2017. Disturbed iron metabolism in erythropoietic protoporphyria and association of GDF15 and gender with disease severity. *J. Inherit. Metab. Dis.* 40(3):433–41
66. Barman-Aksözen J, Minder EI, Schubiger C, et al. 2015. In ferrochelatase-deficient protoporphyria patients, ALAS2 expression is enhanced and erythrocytic protoporphyrin concentration correlates with iron availability. *Blood Cells Mol. Dis.* 54(1):71–77
67. Schmidt PJ, Hollowell ML, Fitzgerald K, et al. 2020. Mild iron deficiency does not ameliorate the phenotype of a murine erythropoietic protoporphyria model. *Am. J. Hematol.* 95(5):492–96
68. Balwani M, Naik H, Overbey JR, et al. 2022. A pilot study of oral iron therapy in erythropoietic protoporphyria and X-linked protoporphyria. *Mol. Genet. Metab. Rep.* 33:100939
69. Delaby C, Lyoumi S, Ducamp S, et al. 2009. Excessive erythrocyte PPIX influences the hematologic status and iron metabolism in patients with dominant erythropoietic protoporphyria. *Cell Mol. Biol.* 55(1):45–52

70. Buzzetti E, Ventura P, Corradini E. 2022. Iron in porphyrias: friend or foe? *Diagnostics* 12(2):272
71. Landefeld C, Kentouche K, Gruhn B, et al. 2016. X-linked protoporphyria: iron supplementation improves protoporphyrin overload, liver damage and anaemia. *Br. J. Haematol.* 173(3):482–84
72. Balwani M, Naik H, Anderson KE, et al. 2017. Clinical, biochemical, and genetic characterization of North American patients with erythropoietic protoporphyria and X-linked protoporphyria. *JAMA Dermatol.* 153(8):789–96
73. Anstey AV, Hift RJ. 2007. Liver disease in erythropoietic protoporphyria: insights and implications for management. *Gut* 56(7):1009–18
74. Cripps DJ, Goldfarb SS. 1978. Erythropoietic protoporphyria: hepatic cirrhosis. *Br. J. Dermatol.* 98(3):349–54
75. Pagano MB, Hobbs W, Linenberger M, et al. 2012. Plasma and red cell exchange transfusions for erythropoietic protoporphyria: a case report and review of the literature. *J. Clin. Apher.* 27(6):336–41
76. McGuire BM, Bonkovsky HL, Carithers RL Jr., et al. 2005. Liver transplantation for erythropoietic protoporphyria liver disease. *Liver Transpl.* 11(12):1590–96
77. Malkiel S, Sayed BA, Ng V, et al. 2021. Sequential paternal haploidentical donor liver and HSCT in EPP allow discontinuation of immunosuppression post-organ transplant. *Pediatr. Transplant.* 25(6):e14040
78. Windon AL, Tondon R, Singh N, et al. 2018. Erythropoietic protoporphyria in an adult with sequential liver and hematopoietic stem cell transplantation: a case report. *Am. J. Transplant.* 18(3):745–49
79. Bonkovsky HL, Schned AR. 1986. Fatal liver failure in protoporphyria. Synergism between ethanol excess and the genetic defect. *Gastroenterology* 90(1):191–201
80. Elder GH. 1998. Porphyria cutanea tarda. *Semin. Liver Dis.* 18(1):67–75
81. Horner ME, Alikhan A, Tintle S, et al. 2013. Cutaneous porphyrias part I: epidemiology, pathogenesis, presentation, diagnosis, and histopathology. *Int. J. Dermatol.* 52(12):1464–80
82. Jalil S, Grady JJ, Lee C, et al. 2010. Associations among behavior-related susceptibility factors in porphyria cutanea tarda. *Clin. Gastroenterol. Hepatol.* 8(3):297–302
83. Phillips JD, Bergonia HA, Reilly CA, et al. 2007. A porphomethene inhibitor of uroporphyrinogen decarboxylase causes porphyria cutanea tarda. *PNAS* 104(12):5079–84
84. Berry AA, Desnick RJ, Astrin KH, et al. 2005. Two brothers with mild congenital erythropoietic porphyria due to a novel genotype. *Arch. Dermatol.* 141(12):1575–79
85. Singal AK, Kormos-Hallberg C, Lee C, et al. 2012. Low-dose hydroxychloroquine is as effective as phlebotomy in treatment of patients with porphyria cutanea tarda. *Clin. Gastroenterol. Hepatol.* 10(12):1402–9
86. Di Padova C, Marchesi L, Cainelli T, et al. 1983. Effects of phlebotomy on urinary porphyrin pattern and liver histology in patients with porphyria cutanea tarda. *Am. J. Med. Sci.* 285(1):2–12
87. Bonkovsky HL, Rudnick SP, Ma CD, et al. 2023. Ledipasvir/sofosbuvir is effective as sole treatment of porphyria cutanea tarda with chronic hepatitis C. *Dig. Dis. Sci.* 68(6):2738–46
88. Katugampola RP, Anstey AV, Finlay AY, et al. 2012. A management algorithm for congenital erythropoietic porphyria derived from a study of 29 cases. *Br. J. Dermatol.* 167(4):888–900
89. Phillips JD, Steensma DP, Pulsipher MA, et al. 2007. Congenital erythropoietic porphyria due to a mutation in GATA1: the first trans-acting mutation causative for a human porphyria. *Blood* 109(6):2618–21
90. Mirmiran A, Poli A, Ged C, et al. 2021. Phlebotomy as an efficient long-term treatment of congenital erythropoietic porphyria. *Haematologica* 106(3):913–17
91. Blouin JM, Ged C, Lalanne M, et al. 2020. Iron chelation rescues hemolytic anemia and skin photosensitivity in congenital erythropoietic porphyria. *Blood* 136(21):2457–68
92. Urquiza P, Laín A, Sanz-Parra A, et al. 2018. Repurposing ciclopirox as a pharmacological chaperone in a model of congenital erythropoietic porphyria. *Sci. Transl. Med.* 10(459):eaat7467
93. D’Avola D, López-Franco E, Sangro B, et al. 2016. Phase I open label liver-directed gene therapy clinical trial for acute intermittent porphyria. *J. Hepatol.* 65(4):776–83
94. Jiang L, Berraondo P, Jericó D, et al. 2018. Systemic messenger RNA as an etiological treatment for acute intermittent porphyria. *Nat. Med.* 24(12):1899–909
95. Neeleman RA, van Beers EJ, Friesema EC, et al. 2019. Clinical remission of delta-aminolevulinic acid dehydratase deficiency through suppression of erythroid heme synthesis. *Hepatology* 70(1):434–36

96. Blouin JM, Ged C, Lalanne M, et al. 2020. Iron chelation rescues hemolytic anemia and skin photosensitivity in congenital erythropoietic porphyria. *Blood* 136(21):2457–68
97. Oustric V, Manceau H, Ducamp S, et al. 2014. Antisense oligonucleotide-based therapy in human erythropoietic protoporphyria. *Am. J. Hum. Genet.* 94(4):611–17
98. Wang P, Sachar M, Lu J, et al. 2019. The essential role of the transporter ABCG2 in the pathophysiology of erythropoietic protoporphyria. *Sci. Adv.* 5(9):eaaw6127
99. Graff E, Anderson KE, Levy C. 2022. Case report: lack of response to givosiran in a case of ALAD porphyria. *Front. Genet.* 13:867856

# Contents

Effects on Cancer Prevention from the COVID-19 Pandemic <i>Stephen W. Duffy, Lucie de Jonge, and Thomas E. Duffy</i> .....	1
New Biological Therapies for Multiple Myeloma <i>Alfred L. Garfall</i> .....	13
Leveraging TROP2 Antibody-Drug Conjugates in Solid Tumors <i>Blessie Elizabeth Nelson and Funda Meric-Bernstam</i> .....	31
Prostate-Specific Membrane Antigen: Gateway to Management of Advanced Prostate Cancer <i>Lena M. Unterrainer, Jeremie Calais, and Neil H. Bander</i> .....	49
Multi-Cancer Early Detection: The New Frontier in Cancer Early Detection <i>Carmen E. Guerra, Prateek V. Sharma, and Brenda S. Castillo</i> .....	67
Novel Therapeutic and Program-Based Approaches to Opioid Use Disorders <i>Patricia Liu, P. Todd Korthuis, and Bradley M. Buchheit</i> .....	83
Lessons Learned from Approval of Aducanumab for Alzheimer's Disease <i>Judith L. Heidebrink and Henry L. Paulson</i> .....	99
Polypharmacy and Deprescribing in Older Adults <i>Wade Thompson and Emily G. McDonald</i> .....	113
Ketamine: Mechanisms and Relevance to Treatment of Depression <i>Ji-Woon Kim, Kanzo Suzuki, Ege T. Kavalali, and Lisa M. Monteggia</i> .....	129
Treatments for COVID-19 <i>Hayden S. Andrews, Jonathan D. Herman, and Rajesh T. Gandhi</i> .....	145
Mpox: The Reemergence of an Old Disease and Inequities <i>J.P. Thornhill, M. Gandhi, and C. Orkin</i> .....	159
More Tailored Approaches to Tuberculosis Treatment and Prevention <i>Charles M. Bark, W. Henry Boom, and Jennifer J. Furin</i> .....	177



Expansion of Anticomplement Therapy Indications from Rare Genetic Disorders to Common Kidney Diseases <i>Takashi Miwa, Sayaka Sato, Madhu Golla, and Wen-Chao Song</i> .....	189
Home-Based Dialysis: A Primer for the Internist <i>Robert Rope, Eric Ryan, Eric D. Weinhandl, and Graham E. Abra</i> .....	205
Novel Antigens and Clinical Updates in Membranous Nephropathy <i>Rupali Avasare, Nicole Andeen, and Laurence Beck</i> .....	219
MELD 3.0 in Advanced Chronic Liver Disease <i>Nikhilesh R. Mazumder and Robert J. Fontana</i> .....	233
Precision Approaches to Chronic Obstructive Pulmonary Disease Management <i>Matthew Moll and Edwin K. Silverman</i> .....	247
Interventional Pulmonology: Extending the Breadth of Thoracic Care <i>Yaron B. Gesthalter and Colleen L. Channick</i> .....	263
Health Effects of Wildfire Smoke Exposure <i>Carlos F. Gould, Sam Heft-Neal, Mary Johnson, Juan Aguilera, Marshall Burke, and Kari Nadeau</i> .....	277
Spectrum of Diabetic Neuropathy: New Insights in Diagnosis and Treatment <i>Brendan R. Dillon, Lynn Ang, and Rodica Pop-Busui</i> .....	293
Emerging Therapies in Hypothyroidism <i>Antonio C. Bianco</i> .....	307
Update on the Porphyrrias <i>Amy K. Dickey, Rebecca Karp Leaf, and Manisha Bakwani</i> .....	321
Carbon Monoxide Poisoning: From Microbes to Therapeutics <i>Matthew R. Dent, Jason J. Rose, Jesús Tejero, and Mark T. Gladwin</i> .....	337
Adverse Impact of Cannabis on Human Health <i>Mark Chandy, Masataka Nishiga, Tzu-Tang Wei, Naomi M. Hamburg, Kari Nadeau, and Joseph C. Wu</i> .....	353
Novel Approaches to Immunomodulation for Solid Organ Transplantation <i>Irma Husain and Xunrong Luo</i> .....	369
The Hospitalist Movement 25 Years Later <i>Shradha A. Kulkarni and Robert M. Wachter</i> .....	381
The Evolving Practice of Hospital at Home in the United States <i>Tuyet-Trinh Truong and Albert L. Siu</i> .....	391

Wearable Devices: Implications for Precision Medicine and the Future of Health Care <i>Mohan Babu, Ziv Lautman, Xiangping Lin, Milan H.B. Sobota, and Michael P. Snyder</i> .....	401
Genetics of Dilated Cardiomyopathy <i>Ramone Eldemire, Luisa Mestroni, and Matthew R.G. Taylor</i> .....	417
New Therapeutic Approaches to Large-Vessel Vasculitis <i>Mahmut S. Kaymakci, Kenneth J. Warrington, and Tanaz A. Kermani</i> .....	427
Management of Resistant Hypertension <i>Lucas Lauder, Felix Mahfoud, and Michael Böhm</i> .....	443
High-Sensitivity Cardiac Troponin Assays: Ready for Prime Time! <i>Konstantin A. Krychtiuk and L. Kristin Newby</i> .....	459
Emerging Technologies in Cardiac Pacing <i>Ramya Vajapey and Mina K. Chung</i> .....	475
Complex Congenital Heart Disease in the Adult <i>Sarah A. Goldstein and Richard A. Krasuski</i> .....	493

## Indexes

Cumulative Index of Contributing Authors, Volumes 71–75 .....	513
Cumulative Index of Article Titles, Volumes 71–75 .....	517

## Errata

An online log of corrections to *Annual Review of Medicine* articles may be found at <http://www.annualreviews.org/errata/med>