

## Smallpox

Simonsen KA, Snowden J.

### Continuing Education Activity

---

Smallpox is the first human infectious disease to be successfully eradicated worldwide. It remains of clinical concern because of the potential for release and weaponization. Smallpox is a member of the viral family poxvirus, genus orthopoxvirus, and species variola virus. This disease presents with a non-specific febrile prodrome of high fever, chills, vomiting, abdominal pain, headache, and backache. The skin lesions occur 1-3 days later and first begin on the forearms or face and spread to the rest of the body. This activity illustrates the evaluation and treatment of smallpox and describes the role of the interprofessional team in managing those with this condition.

#### Objectives:

- Describe the epidemiology of small pox.
- Review the presentation of a patient with small pox.
- Summarize the treatment of small pox.
- Outline the importance of collaboration and communication among the interprofessional team members to be aware of the clinical presentation of smallpox and report it efficiently to prevent an outbreak of this disease.

[Access free multiple choice questions on this topic.](#)

### Introduction

---

Smallpox is the first human infectious disease to be successfully eradicated worldwide, and the World Health Assembly certified its global eradication in 1980.[1] It remains of clinical importance because of concerns about the potential for release and weaponization.[2]

### Etiology

---

Smallpox is a member of the viral family poxvirus, genus orthopoxvirus, and species variola virus. Poxviruses are the largest of the human viral pathogens and have a brick-shaped appearance on electron microscopy. Variola virus measures approximately 300 nm to 350 nm long. The poxviruses possess a linear, double-stranded DNA genome, and are unique in that their genetic makeup encodes all the proteins necessary for replication allowing them to replicate in the host cell cytoplasm.[3]

### Epidemiology

---

Smallpox is a human disease without animal reservoirs, which became an important factor in its successful eradication. In the late 1700s, Edward Jenner successfully demonstrated that cowpox virus could vaccinate people against smallpox. Vaccinia virus eventually replaced cowpox as the viral agent used for smallpox vaccination; although genetically distinct from cowpox, the origins of vaccinia are uncertain. In the 20 century, prior to eradication, the global death toll was over 300 million. Case fatality rates were approximately 30% overall, although survivors frequently suffered significant morbidity including blindness and skin scarring. The last naturally-occurring case of smallpox was found in Somalia in 1977.[4]

Smallpox transmission occurs through airborne respiratory droplet secretions or direct contact with lesions or contaminated fomites. Infectious viral particles are released from sloughing of oropharyngeal lesions and resultant aerosolization of viral particles. Transmission can occur from the onset of lesions until all crusts have sloughed. Airborne transmission in hospital and laboratory settings has been described, and smallpox requires enhanced infection control and isolation precautions.[5]

### Pathophysiology

---

After viral entry through the oropharynx or nasopharynx, the virus migrates to regional lymph nodes where it begins replication. An initial viremia occurs on day 3 to 4 after infection, and the virus further disseminates to the bone marrow, spleen, and additional lymph node chains. A secondary viremia occurs between day 8 to 12 after infection and coincides with the onset of fever and clinical evidence of illness. At this stage, the virus becomes localized in the oropharyngeal mucosa and small blood vessels of the dermis, resulting in the onset of rash and clinical infectiousness.[6]

## History and Physical

---

Clinical manifestations of smallpox begin with non-specific febrile prodrome including high fever, chills, abdominal pain and vomiting, headache and backache. The febrile prodrome occurs 1 to 3 days before the onset of skin lesions. The emergence of skin lesions begins on the forearms or face and then spreads to the rest of the body, with palms and soles frequently involved. Lesions are most numerous on the extremities and face with fewer lesions on the torso. Lesions on one portion of the body emerge and evolve at the same stage of development throughout the illness. Individual skin lesions change from macules to papules, to vesicles, to pustules, to crusts with approximately 48 hours elapsing between stages. Crusting of all lesions is typically complete 2 to 3 weeks after the initial onset of rash. The lesions appear deep-seated, round, firm, well-circumscribed and approximately 7 mm to 10 mm in diameter.[7][6]

## Evaluation

---

The Centers for Disease Control and Prevention (CDC) has developed an evaluation tool for clinicians caring for patients presenting with a rash illness that resembles smallpox based upon major and minor criteria. Major criteria for smallpox include febrile prodrome, classic lesion appearance, and lesions in the same stage of development. Minor criteria include centrifugal (distal extremities and face) distribution of the rash, the initial appearance of lesions on oral mucosa or palate, face or forearms, the presence of rash on palms and soles, slow rash evolution (1 to 2 days per stage) and toxic appearance. Based on these criteria patients are described as having a low, moderate, or high risk for smallpox with recommendations for diagnostic testing based upon classification. [8]Laboratory testing is not recommended for low or moderate risk patients in the absence of known smallpox circulation. For patients in whom testing is recommended, PCR from serum or whole blood as well as tissue samples may be recommended after public health consultation.[6][7]

## Treatment / Management

---

Prior to eradication, supportive care was the primary treatment available. In the post-eradication era, development of anti-orthopoxvirus medical therapies remains an active area of research. In 2018, the United States approved tecovirimat as the first antiviral therapy indicated for treatment of smallpox. [9] Although the antiviral has only been evaluated fully in animal models, it has been administered to human volunteers in a safety trial, and as an emergency investigational drug to patients who developed post-vaccination complications.[9][10][11]

Vaccination has been successful in the eradication of smallpox globally. There have been several smallpox vaccines developed over time, beginning with variolation, the deliberate inoculation of infectious smallpox from the pustule of an infectious person to a healthy, nonimmune contact to induce a more mild disease course. Descriptions of variolation are found from as early as 1500 BC. This practice carried significant risk including severe disease and mortality as well as the potential for community spread of infection. In 1798, Edward Jenner's publication of his research confirming that cowpox protected against smallpox infection led to the adoption of cowpox vaccination. By 1900, cowpox was no longer the virus used for vaccination, but vaccinia virus, which is more closely related to horsepox. Vaccinia became the virus used for large-scale global vaccination programs during the 20th century, but potential risks persisted.[12]

Vaccine-associated adverse events from live vaccinia virus can be serious and include generalized vaccinia, eczema vaccinatum, progressive vaccinia, and postvaccinial encephalitis. Vaccine adverse events can also cause symptoms in others through contact with vaccine site and unintended inoculation, or from vaccinated mother to fetus.[13][14]

Post-eradication, vaccine researchers have utilized improved technology to develop tissue-culture-based live vaccines, live attenuated virus vaccines, and viral subunit vaccine products. These are necessary to improve vaccine safety within the global context of an eradicated infection. Current smallpox vaccine recommendations include only personnel at increased special risk of exposure such as researchers, some healthcare workers, and some United States military personnel.[12]

## Differential Diagnosis

---

Distinguishing smallpox from similar rashes remains an important perspective for practicing clinicians. The differential diagnosis of smallpox includes chickenpox, HSV-disseminated or eczema herpeticum, VZV-disseminated zoster, enteroviral hand-foot-mouth syndromes, drug eruptions including Stevens-Johnson or toxic epidermal necrolysis, generalized vaccinia and monkeypox.[6]

## Pearls and Other Issues

---

Remaining variola virus stock has been restricted to the WHO Collaborating Centers on Smallpox and other Poxvirus Infections at the CDC and the Russian State Research Centre of Virology and Biotechnology (SRC VB VECTOR) labs. After the events of Sept. 11, 2001 in the United

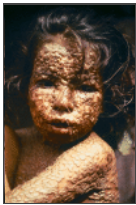States, the concern arose for the deliberate release of the virus as an act of bioterrorism, and research for medical countermeasures including vaccines and anti-viral medications was renewed.[12]

## Enhancing Healthcare Team Outcomes

It is hoped no healthcare professional will ever encounter smallpox. That being said an interprofessional team of emergency nurses and clinicians, in the front lines, need to be aware of the presentation so that if it does occur, it will be reported quickly so that an appropriate response can be undertaken to minimize the outbreak. [Level V]

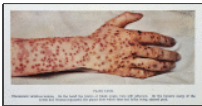## Review Questions

- Access free multiple choice questions on this topic.
- Comment on this article.



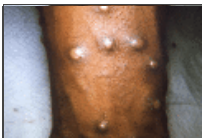### Figure

This young girl in Bangladesh was infected with smallpox in 1973, Freedom from smallpox was declared in Bangladesh in December, 1977 when a WHO International Commission officially certified that smallpox had been eradicated from that country. Contributed (more...)



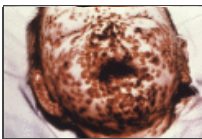
### Figure

Obsolescent variolous lesions, smallpox. Contributed by Wikimedia Commons, Wellcome Trust (1908), (CC BY 4.0)



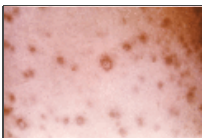
### Figure

Pathology, Maculopapular lesions, arm, Smallpox Virus, Pustular phase, Variola major and minor. Contributed by Dr. John Noble, Jr., The Centers for Disease Control and Prevention (CDC)



### Figure

Face of a one year-old infant, Child, Smallpox virus, Dermatological manifestation, benign semi-confluent variola, 10th day post-onset, Variola Major and Minor. Contributed by Dr. Charles Farmer, Jr., The Centers for Disease Control and Prevention (CDC) (more...)



### Figure

Pathology, Variola Major and Minor, Smallpox virus, Violaceous lesions, Lichenoid, Maculopapular manifestations. Contributed by Dr. Charles Farmer, Jr., The Centers for Disease Control and Prevention (CDC)

## References

1. Henderson DA. The eradication of smallpox--an overview of the past, present, and future. *Vaccine*. 2011 Dec 30;29 Suppl 4:D7-9. [PubMed: 22188929]
2. Lane JM, Poland GA. Why not destroy the remaining smallpox virus stocks? *Vaccine*. 2011 Apr 05;29(16):2823-4. [PubMed: 21376120]
3. Voigt EA, Kennedy RB, Poland GA. Defending against smallpox: a focus on vaccines. *Expert Rev Vaccines*. 2016 Sep;15(9):1197-211. [PMC free article: PMC5003177] [PubMed: 27049653]

4. Eyster JM. Smallpox in history: the birth, death, and impact of a dread disease. *J Lab Clin Med*. 2003 Oct;142(4):216-20. [PubMed: 14625526]
5. Milton DK. What was the primary mode of smallpox transmission? Implications for biodefense. *Front Cell Infect Microbiol*. 2012;2:150. [PMC free article: PMC3509329] [PubMed: 23226686]
6. Moore ZS, Seward JF, Lane JM. Smallpox. *Lancet*. 2006 Feb 04;367(9508):425-35. [PubMed: 16458769]
7. Breman JG, Henderson DA. Diagnosis and management of smallpox. *N Engl J Med*. 2002 Apr 25;346(17):1300-8. [PubMed: 11923491]
8. Seward JF, Galil K, Damon I, Norton SA, Rotz L, Schmid S, Harpaz R, Cono J, Marin M, Hutchins S, Chaves SS, McCauley MM. Development and experience with an algorithm to evaluate suspected smallpox cases in the United States, 2002-2004. *Clin Infect Dis*. 2004 Nov 15;39(10):1477-83. [PubMed: 15546084]
9. Grosenbach DW, Honeychurch K, Rose EA, Chinsangaram J, Frimm A, Maiti B, Lovejoy C, Meara I, Long P, Hruba DE. Oral Tecovirimat for the Treatment of Smallpox. *N Engl J Med*. 2018 Jul 05;379(1):44-53. [PMC free article: PMC6086581] [PubMed: 29972742]
10. Mucker EM, Goff AJ, Shamblin JD, Grosenbach DW, Damon IK, Mehal JM, Holman RC, Carroll D, Gallardo N, Olson VA, Clemmons CJ, Hudson P, Hruba DE. Efficacy of tecovirimat (ST-246) in nonhuman primates infected with variola virus (Smallpox). *Antimicrob Agents Chemother*. 2013 Dec;57(12):6246-53. [PMC free article: PMC3837858] [PubMed: 24100494]
11. Vora S, Damon I, Fulginiti V, Weber SG, Kahana M, Stein SL, Gerber SI, Garcia-Houchins S, Lederman E, Hruba D, Collins L, Scott D, Thompson K, Barson JV, Regnery R, Hughes C, Daum RS, Li Y, Zhao H, Smith S, Braden Z, Karem K, Olson V, Davidson W, Trindade G, Bolken T, Jordan R, Tien D, Marcinak J. Severe eczema vaccinatum in a household contact of a smallpox vaccinee. *Clin Infect Dis*. 2008 May 15;46(10):1555-61. [PubMed: 18419490]
12. Melamed S, Israely T, Paran N. Challenges and Achievements in Prevention and Treatment of Smallpox. *Vaccines (Basel)*. 2018 Jan 29;6(1) [PMC free article: PMC5874649] [PubMed: 29382130]
13. Mota BE, Gallardo-Romero N, Trindade G, Keckler MS, Karem K, Carroll D, Campos MA, Vieira LQ, da Fonseca FG, Ferreira PC, Bonjardim CA, Damon IK, Kroon EG. Adverse events post smallpox-vaccination: insights from tail scarification infection in mice with Vaccinia virus. *PLoS One*. 2011 Apr 15;6(4):e18924. [PMC free article: PMC3078145] [PubMed: 21526210]
14. Wollenberg A, Engler R. Smallpox, vaccination and adverse reactions to smallpox vaccine. *Curr Opin Allergy Clin Immunol*. 2004 Aug;4(4):271-5. [PubMed: 15238792]

## Publication Details

### Author Information

#### Authors

Kari A. Simonsen<sup>1</sup>; Jessica Snowden<sup>2</sup>.

#### Affiliations

<sup>1</sup> University of Nebraska Medical Center

<sup>2</sup> University of Nebraska Medical Center

### Publication History

Last Update: August 14, 2021.

### Copyright

Copyright © 2021, StatPearls Publishing LLC.

This book is distributed under the terms of the Creative Commons Attribution 4.0 International License (<http://creativecommons.org/licenses/by/4.0/>), which permits use, duplication, adaptation, distribution, and reproduction in any medium or format, as long as you give appropriate credit to the original author(s) and the source, a link is provided to the Creative Commons license, and any changes made are indicated.

### Publisher

StatPearls Publishing, Treasure Island (FL)

### NLM Citation

Simonsen KA, Snowden J. Smallpox. [Updated 2021 Aug 14]. In: StatPearls [Internet]. Treasure Island (FL): StatPearls Publishing; 2021 Jan-.