



Newborn infant skin: Physiology, development, and care



Marty O. Visscher, PhD^{a,*}, Ralf Adam, PhD^b, Susanna Brink, PhD^b, Mauricio Odio, PhD^c

^a*Skin Sciences Program, Division of Plastic Surgery, Cincinnati Children's Hospital Medical Center, Cincinnati, OH*

^b*The Procter & Gamble Company, Schwalbach, Germany*

^c*The Procter & Gamble Company, Cincinnati, OH*

Abstract Infant skin is critical to the newborn child's transition from the womb environment to the journey to self-sufficiency. This review provides an integrative perspective on the skin development in full term and premature infants. There is a particular focus on the role of vernix caseosa and on the implications of skin development for epidermal penetration of exogenous compounds. Healthy full-term newborn skin is well-developed and functional at birth, with a thick epidermis and well-formed stratum corneum (SC) layers. Transepidermal water loss is very low at birth, equal to, or lower than adults, indicating a highly effective skin barrier. Vernix facilitates SC development in full-term infants through a variety of mechanisms including physical protection from amniotic fluid and enzymes, antimicrobial effects, skin surface pH lowering, provision of lipids, and hydration. Premature infants, particularly those of very low birth weight, have a poor skin barrier with few cornified layers and deficient dermal proteins. They are at increased risk for skin damage, increased permeability to exogenous agents and infection. The SC barrier develops rapidly after birth but complete maturation requires weeks to months. The best methods for caring for infant skin, particularly in the diaper region, are described and related to these developmental changes.

© 2015 Elsevier Inc. All rights reserved.

Introduction

At birth, a newborn infant goes from the warm, wet, sterile, and safe womb to a cooler, dry, bacteria-laden nursery; concurrently the baby begins the journey to self-sufficiency by breathing air, taking nutrition, and maintaining body temperature. Newborn skin is critical to this transition and performs many functions, including: (1) barrier to water loss, light, and irritants; (2) infection control and immunosurveillance; (3) resilience to mechanical trauma; (4) sensation and

tactile discrimination; (5) thermal regulation; and (6) acid mantle formation.

In the context of neonatal skin development, the question of maturity of the epidermal barrier, at birth, is not yet fully resolved. Some authors affirm that, at birth, the skin is immature relative to the adult human,¹ whereas others report evidence consistent with the view that infants are born with a fully or near fully competent epidermal barrier.² Although the former may find distinctions between adult and infant skin (such as differences in natural moisturizing factors [NMF] or content and size of corneocytes),³ evidence from the latter is more limited, given that functional end point measurements often require invasive procedures that pose ethical limitations in the context of pediatric research.

* Corresponding author.

E-mail address: marty.visscher@cchmc.org (M.O. Visscher).

As a viable alternative to more invasive procedures, transepidermal water loss (TEWL), that is, the rate at which water vapor from respiration passes through the skin layers into the environment (Figure 1), is generally accepted as a robust indicator of epidermal barrier function and skin integrity.⁴ Normal TEWL is 4 to 8 g/m²/hr^{5,6} with lower values generally indicating an effective stratum corneum (SC) barrier, and high values meaning the barrier is damaged, not well formed, or has fewer than the normal 16 layers. Evidence from age-related TEWL studies support the predominant view that infant skin barrier function, at birth⁶ or very soon thereafter (within 2–4 weeks), is in the same range as that of healthy adults.^{6–9} These observations on skin barrier condition in the healthy newborn align well with reports that neonates and young infants tolerate and respond well to a variety of skin-cleansing regimens.^{10,11} Even so, less than universal consensus on the question of neonatal epidermal barrier maturity may help to explain differential opinions about care practices for newborn infant skin,¹² as well as variations in clinical practice.

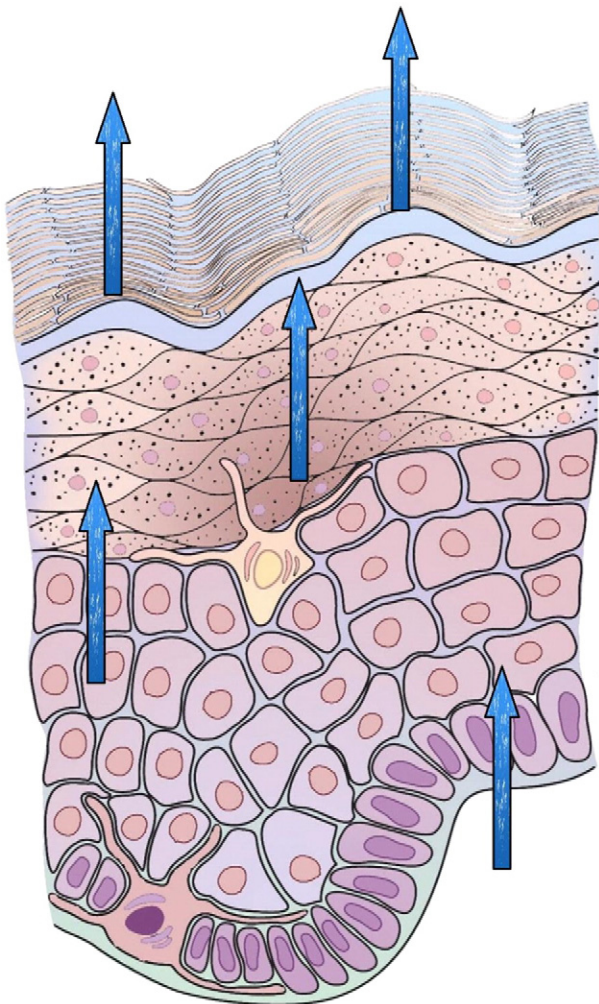


Fig. 1 Transepidermal water loss (TEWL).

This review provides an integrative perspective on the structure and development of skin from the preterm to the full-term infant with a particular focus on the role of vernix caseosa and on implications of skin development for epidermal penetration of exogenous compounds.

Physiology and development of newborn infant skin

Skin structure

Infant skin consists of three major layers, the SC, the viable epidermis and the dermis, and specialized cells within them, as shown in Figure 2. The SC is in direct contact with the environment and is the main barrier to water loss and penetration by outside agents. Langerhans cells (antigen presenting immune cells) serve as the first line of defense if the SC is breached. The melanocytes (pigment cells) in the lower part of the epidermis produce melanin, the pigment responsible in part for inherent skin color.

When the skin is exposed to sunlight (ultraviolet radiation), melanocytes are activated and transport melanin to shield the living epidermal cells, protecting the DNA. Skin darkening (tanning) is a result of this process. The pigimentary system is also influenced by irritation and inflammation by producing more pigment (hyperpigmentation) or by deactivation (resulting in hypopigmentation). By design, the outermost SC is difficult to penetrate and provides a barrier to liquid water loss while allowing water vapor (transepidermal water) to be lost. The SC has about 16 layers of flattened cells (corneocytes), joined together by molecular “rivets” called desmosomes below.^{13,14} Lipids (cholesterol, fatty acids, ceramides) are secreted from the lamellar bodies into the spaces between the corneocytes to form a regular “brick (cells) and mortar (lipids)” structure. The lipids form a regular, ordered bilayer structure alternating with water between the cells. The epidermis continually builds and replenishes the SC as the outermost cells are released from the surface through desquamation.

Full-term infant skin

Despite being exposed to water and amniotic fluid for 9 months, full-term newborn skin is well-developed and functional at birth, with thick epidermis and well-formed SC layers.^{15,16} TEWL in healthy full-term infants is very low at birth (equal to or lower than adults), indicating a highly effective skin barrier.^{6–9,17,18}

This raises the question of how this excellent barrier develops while continuously immersed in water. This is particularly intriguing, because in the extra-uterine environment (ex utero) continuous exposure to water causes significant skin damage (including maceration of the SC and disruption of its well-organized structure) and injury to the epidermis. It actually prevents the formation of new SC. Ex utero, air exposure

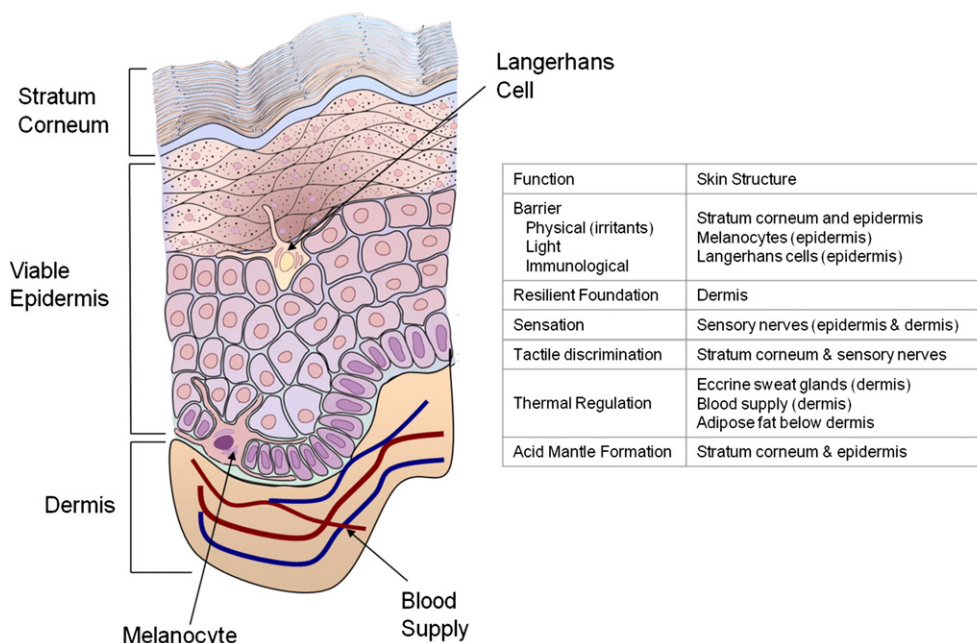


Fig. 2 Structure of skin.

stimulates the formation of new SC after injuries such as abrasions, where the barrier is completely removed. In utero, absence of air exposure and continuous water immersion do not impede SC formation.

Infant skin development—vernix caseosa

During the last trimester, vernix caseosa begins to coat the skin from head-to-toe and back-to-front. The vernix coating protects the epidermis from water exposure and creates a drier condition, which may allow the SC protective barrier to form.¹⁹ Vernix is a complex mixture of 80% water, 10% protein, and 10% lipids consisting of cells coated with an amorphous mixture of lipids.²⁰ Its remarkably high water content is associated with the cells, and hormones from the mother and placenta likely control its formation. The vernix caseosa lipid-cell mixture is squeezed out through the hair shaft onto the skin (epidermis) surface and spreads over the entire surface as production continues.²¹ Vernix is hydrophobic (water-repelling) due to the lipids, which cover the hydrated cells.²²

Vernix has several other functions.²³ It contains antimicrobial agents including lysozyme and lactoferrin and exhibits a range of bioactivity against common fungal and bacterial pathogens.^{24–27} In some settings, vernix is removed immediately after birth. Reported evidence suggests there may be value in reconsidering this practice. One study found that vernix retention, compared to vernix removal immediately after birth, led to significantly higher skin hydration 24 hours after birth and lower skin pH, suggesting that vernix assists in acid mantle development.¹⁹

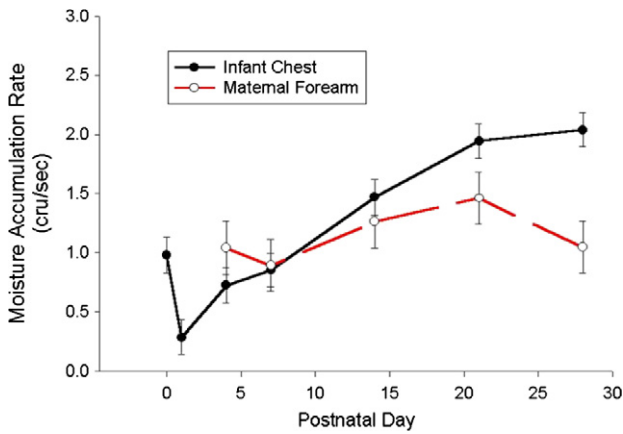
Other research has shown that vernix treatment of adult volar forearm skin increased SC water binding capacity,²⁸ and native

vernix treatment of SC wounds (tape stripped skin) assisted barrier repair relative to controls and demonstrated wound-healing properties.^{29–31} In model systems, vernix enhanced SC formation without increasing epidermal thickness.^{30,31} Films of vernix impeded the penetration of the exogenous enzyme chymotrypsin (found in meconium, similar proteolytic enzymes present in feces) and maintained the activity of native enzymes (necessary for epidermal development) *in vitro*.³² Vernix contains the cytokines interleukin-1 alpha and beta (IL-1 α , IL-1 β), tumor necrosis factor alpha (TNF α), interleukin-6 (IL-6), interleukin-8 (IL-8), and monocyte chemotactic protein-1 (MCP1),³³ as well as cholesterol, ceramides, and a number of fatty acids (including oleic, linoleic, and long-chain species).^{26,34} Fatty acids (particularly linoleic, which has antiinflammatory properties³⁵) activate peroxisome proliferator-activated receptor-alpha (PPAR α), which increases the rate of barrier formation.³⁶

Overall, the vernix facilitates development of the SC protective barrier in normal, full-term infants through a variety of protective and adaptive mechanisms. These findings support the practice of vernix retention for at least 6 hours (rather than removal) at birth, as recommended by the World Health Organization.³⁷

Newborn skin adaptation after birth

Adequate SC hydration is essential for plasticity and flexibility during movement, to prevent cracking and for desquamation of the outermost layer.^{38,39} Soon after birth, newborn skin hydration varies by body site (chest, back, forehead), time under the radiant warmer, and the presence of vernix.^{2,8,19,40,41} Skin hydration decreases rapidly in the first



Source: Visscher et al, 2000^[44]

Fig. 3 Skin hydration of newborn versus mother's skin. Source: Visscher et al.⁴⁴

day and then increases during the first 2 weeks, in contrast to mother's skin, where hydration is quite constant (Figure 3). Water binding ability also increases during the first 14 days. Newborn skin is significantly drier than the skin of older infants (1, 2, and 6 months) and the mothers.^{1,2,42,43} These changes in hydration and water binding indicate that the skin is adapting to the new environment.⁴⁴ Skin dryness and peeling is commonly observed for infants of post-term gestation. Infants of 41 to 42 weeks gestation had significantly lower amounts of vernix at birth.¹⁹ Consequently, post-term neonatal skin may experience a long period of hydration by amniotic fluid. Frequent exposure to water disrupts the SC lipid bilayer architecture.⁴⁵ In response, the epidermis up-regulates SC formation, resulting in hyperproliferation and inadequate desquamation.⁴⁶ Prolonged water exposure in utero may contribute to post-term skin dryness.

Low hydration may result from several interacting factors including lack of water binding molecules in the upper SC due to extraction into the amniotic fluid in utero^{47,48} and/or to delayed or impaired filaggrin proteolysis at high humidity.⁴⁹ To identify possible causes, the levels of water-binding free amino acids (FAA) in infant SC have been measured. The FAA constitutes about 40% of NMF, a mixture of low molecular weight, hygroscopic products of filaggrin proteolysis in the SC. In the absence of vernix, FAA levels were extremely low at birth, increased over the first month but remained markedly lower than typical adult levels.^{50,51} FAAs were significantly lower across ten layers of neonatal foreskin compared to adult volar forearm skin. The finding of reduced FAAs in neonates at birth and 1 month extends the finding of lower NMF in 3- to 12-month-old infants versus adults with Raman confocal microspectroscopy.¹

Native vernix contains FAA, and newborn skin with vernix has significantly higher levels of FAA 24 hours after birth compared to skin with vernix removed, paralleling the higher skin hydration.⁵¹ FAAs in vernix caseosa-retained skin are attributed to the vernix rather than to proteolysis of filaggrin in the upper stratum corneum secondary to a

reduction in ambient humidity.⁴⁹ Vernix provides water binding moieties (FAAs) that can facilitate the sudden adaptation from amniotic fluid immersion in utero to the dry ambient conditions after birth.

An acid surface is necessary for the effective functioning of enzymes in stratum formation and integrity, that is, lipid metabolism, bilayer structure, ceramide synthesis, and desquamation,^{52,53} for bacterial homeostasis, skin colonization, and inhibition of pathogenic bacteria.^{54–56} Full-term infant skin acidity (pH) is relatively neutral at birth, decreases significantly during the first 1 to 4 days, and continues to drop during the first 3 months, as the enzymes needed to generate acidic components are activated.^{18,44,57} Acidification via free fatty acids is required for SC-cell cohesion while an increased pH may reduce SC integrity and enhance susceptibility to mechanical trauma.⁵⁵ Topical treatment of the SC with PPAR α activators increases the rate of skin pH lowering after birth in neonatal animals, demonstrating that the adaptive mechanisms can be influenced with exogenous materials.⁵⁸ Acidification of the SC enhances its integrity and cohesion, in part by increasing lipid processing⁵⁹ improves SC barrier homeostasis in neonatal as well as aged skin.⁶⁰ The application of acidic treatments has been proposed as a method for treating skin inflammation, barrier disruption and for normalizing SC structure and function.⁵⁹ The antimicrobial protein lysozyme is present in newborn SC at levels five times higher than adults and its activity was not altered with routine bathing.⁶¹ For this reason, newborn skin is part of the innate immune system and to the infant's defense against bacterial infections.

Premature infant skin

Unlike a full-term baby, the premature infant has a poor epidermal barrier with few cornified layers and is at risk for increased permeability to exogenous materials, additional skin damage, delayed barrier maturation, and infection.^{62,63} The dermis is deficient in structural proteins, the mechanical properties are poor, and the skin is easily torn.⁶⁴ The SC structural integrity is related to gestational age at birth. Preterm SC formation is rapid with exposure to a dry environment^{65,66} and certain neonatal intensive care unit (NICU) practices (eg, incubator humidity) facilitate SC barrier maturation.⁶⁷ Babies born prematurely (ie, <28 weeks) do not have the covering of vernix.

Very low birth weight infants are at greatest risk for skin damage. At 23 weeks, the SC is nearly absent with TEWL of 75 g/m²/hr (Figure 4).⁶⁸ By week 26, a few cornified layers have formed (TEWL of ~45 g/m²/hr), indicating a wounded skin surface.^{62,63} At 29 weeks, TEWL is 17 g/m²/hr and markedly higher than values of 4 to 6 g/m²/hr observed in full-term infants. Around weeks 34 and 35, the barrier is relatively well-formed.

Poor SC integrity increases the risk of high water loss, electrolyte imbalance, thermal instability, and increased exposure to irritants and infectious agents (due to increased permeability). After birth, the barrier continues to develop,

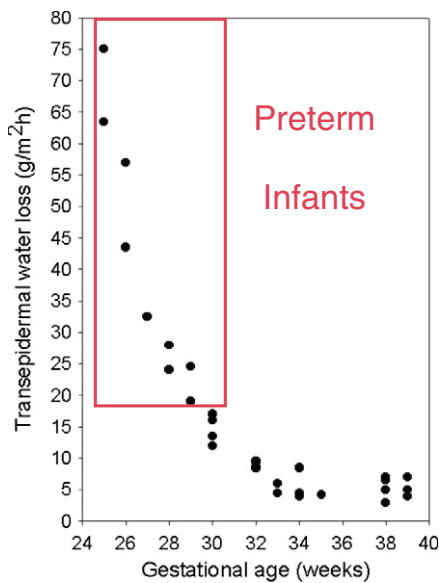


Fig. 4 Transepidermal water loss (TEWL) of preterm infants. Reproduced with permission from Sedin et al.⁶⁸

but even after 1 month TEWL is significantly higher than normal full-term infants.⁶⁷ Skin hydration is significantly higher for infants < 30 weeks gestational age than infants > 30 weeks due to high amounts of water passing through the skin.⁶⁶ By day 5 of life, skin hydration is significantly lower for premature infants (ie, <27 weeks gestational age) indicating rapid barrier development. Environmental humidity influences the rate and quality of SC barrier maturation. Low humidity (10% relative humidity, animal model) led to reduced hydration and increased epidermal DNA synthesis indicating that low hydration triggers cell proliferation.⁶⁹ The time to complete barrier maturation may be as long as 9 weeks postnatal age^{65,70–72} and longer for complete acid mantle formation.⁷³

Clinically, abnormal desquamation (ie, large scales indicative of SC hyperproliferation) is noted for very premature infants and may occur for several weeks after birth. Humidity affects the breakdown of filaggrin in the epidermis to form NMF which, in turn, hydrates the skin.⁷⁴ NMF levels are likely to be quite low under the conditions of rapid skin development for premature infants in low humidity settings, based on results of newborn animal studies.⁴⁹

Dermal absorption/penetration

Soon after birth, the SC of the full-term infant is remarkably capable of providing an effective semi-permeable barrier between the inside and outside of the body.^{8,57,65} On the basis of TEWL and dermal absorption studies, term infants seem to possess a fully developed, competent SC^{8,63} with adult barrier properties.⁶⁵ Certain features, including skin thickness, acidity (pH), and hydration, progressively adapt during the first weeks and months of life. Importantly, though, these adaptations do

not appear to prevent a fully competent barrier function from being expressed in the term neonate.

The diaper area and nondiapered regions are indistinguishable at birth but show differential behavior over the first 14 days, with the diapered region having a higher pH and increased hydration.^{3,8,44} Differences in skin pH change the ionization grade of molecules and will influence dermal absorption.^{75,76} Hydration favors penetration of hydrophilic substances. Despite modern improvements in diaper technology,^{77–79} irritant diaper dermatitis cannot completely be avoided, and the resulting damage to the epidermal barrier may potentially favor dermal absorption of xenobiotics. A number of molecules, which historically have been used in the diaper area, are known to induce systemic toxicity and should only be used very carefully and only when indicated (eg, hexachlorophene, dichlorophene, corticosteroids, boric acid, and ethanol).^{80,81} Innovative hygiene absorbent and baby care products, however, provide an increasingly good skin compatibility profile, which in recent years seem to have reduced the frequency and severity of diaper dermatitis.^{82–84}

Care of newborn skin

Bathing

Skin cleansing products usually contain surfactants that remove dirt and soils with rinsing. Because they emulsify lipids, surfactants can damage the SC lipids, increasing skin permeability and causing skin irritation (Figure 5). Surfactants skin irritancy varies from “mild” or “minimally damaging” to very harsh and can remain on the skin after bathing.⁸⁵ There is evidence that bathing is superior to washing and that add-on of syndets or liquid baby cleansers may be superior to bathing in water alone.¹⁰ Recommendations for infant bathing include use of liquid products with very low irritancy surfactants, minimizing the amount used,¹⁶ rinsing well, and avoiding “over bathing” (ie, multiple exposures in a short period).

Diaper skin care

Reduction of diaper skin moisture is essential for maintaining healthy skin.⁸⁶ Disposable diapers absorb urine/moisture, wick it away from the skin, and prevent rewetting over time.⁸⁷ The net effect is decreased humidity and skin hydration. Infant diapering practices have evolved from the use of (1) cloth (covered with plastic, impermeable over pants); to (2) disposable diapers with a cellulose core and a plastic outer cover; to (3) disposable diapers with highly absorbent polymers (known as superabsorbent polymers/materials); and to (4) absorbent gelling material diapers with a permeable or “breathable” outer cover.^{77–79,88–90}

Disposable diapers with superabsorbent polymers/materials have consistently reduced wetness, lowered rash scores, and lowered skin pH compared to other types of disposables and cloth. As diaper technology has evolved, the frequency of

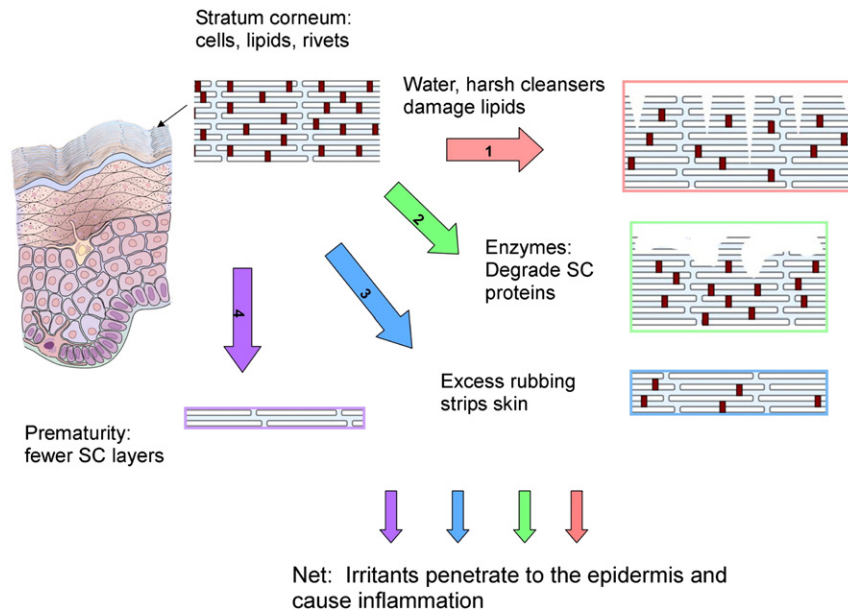


Fig. 5 Insults to infant skin.

severe diaper dermatitis has decreased.^{79,82,89} With cloth, severe dermatitis was 60% in contrast to 39% for cellulose disposables, 29% for superabsorbent disposables and 13% for superabsorbent polymer diapers with a breathable outer cover.^{88,91} Moderate rash went from 35% with cloth to 53% for cellulose and 56% for superabsorbent disposables, reflecting reduction in severe cases. Moderate dermatitis decreased to 32% for superabsorbent polymer diapers with breathable covers.⁸⁸ Severe diaper dermatitis, including dermatitis associated with *Candida albicans*, was reduced by 38% to 50% among infants in disposables with a breathable outer cover and the reduction was directly related to the technical breathability, a condition unfavorable to *C. albicans* survival.⁹²

Diaper region environment

Several features of the diaper environment predispose the skin for damage, as illustrated in [Figure 5](#). Overhydration, urine, feces, friction, increased skin pH, and diet, are detrimental to skin integrity via disruption of the SC lipids and ceramides leading to increased penetration and epidermal inflammation.^{42,93–96} Consequently, significantly higher IL-1 α levels were detected in the diapered skin compared to nondiapered skin.⁹⁵ Fecal enzymes can degrade SC proteins and cause inflammation.⁹⁷ Skin compromise triggers SC repair and initially results in hyperproliferation, a defective architecture, aberrant water binding properties, insufficient hydration, and inadequate desquamation; that is, until the normal homeostasis is restored. Development of diaper products should aim at increased speed and capacity of absorption and containment of excreta. Additional features such as inner liners with barrier cream preparations and breathable outer covers also help maintain skin homeostasis.⁸⁷

Cleansing the diaper region

Diapered skin can be cleansed with a soft cloth and oil-in-water lotion to assist in soil removal.⁸⁶ Cleansing with wipes of soft nonwoven substrate with water and emollient cleansers led to decreased skin irritation in a general population, atopic babies, and hospitalized premature and full-term neonates compared to cloth and water cleansing.^{73,98} Significantly lower TEWL indicated a more normalized SC barrier for wipes than for cloth and water. Well-formulated baby wipes are appropriate and effective for diaper skin care among similar NICU infants. Wipe treatment (substrate with cleansers and/or emollients) resulted in significantly lower erythema and roughness compared to water plus an implement (cotton washcloth, cotton wool balls) in healthy infants and infants with medically confirmed atopic dermatitis.^{84,98,99} Recent developments indicate a central role of skin pH homeostasis by baby wipes fighting etiologic factors for diaper rash but also supporting pH-driven physiologic enzymatic processes within SC restoration.¹⁵ Wipes used on diaper skin should contain only essential materials and be free of alcohol (except mild alcohols such as benzyl alcohols), Kathon CG (The Dow Chemical Company)/methylchloroisothiazolinone/methylisothiazolinone, fragrance, and ingredients of known irritancy or cytotoxicity.^{15,100}

Diaper dermatitis

The majority of diaper dermatitis is irritant contact dermatitis,¹⁰¹ whose resolution is based on early intervention and minimizing or eliminating the etiologic causes. The presence of infection (eg, yeast, bacterial) must first be

determined, and appropriate medical intervention obtained based on the infectious organism. The dermatitis due to *C albicans* typically includes bright red color, patchy pattern (areas may be surrounded by scales), and pustules. For irritant dermatitis, the goal is to allow for restoration despite continuing exposure to the offending agents. Ideally, topical treatments: (1) provide a semipermeable “film” over the damaged skin to allow the skin to repair itself; (2) provide a physical shield between the skin and the irritants, (3) remain in place on the skin (not removed by feces), and (4) allow for ease of skin cleansing (minimize stripping). Skin repair occurs more quickly when treated with barriers, creams, or films that are semipermeable to water vapor, because complete occlusion can delay healing.^{102,103} Some of these principles have been creatively integrated into diaper designs in the past decades including lotion-impregnated inner liners and water permeable outer covers, which contribute to lower relative humidity in the diaper.^{77,78,83,92}

Emollients

The practice of emollient application to infant skin varies globally. For example, oil massage is common in India. Oils, such as sunflower, safflower, sesame, and apricot contain fatty acids, particularly linoleic acid which has antiinflammatory properties,³⁵ increases the rate of SC barrier formation.^{14,36} The application of sunflower seed oil to the skin of premature infants who are less than 33 weeks gestational age at birth reduced the incidence of nosocomial blood infections by 41% in developing countries.¹⁰⁴ Application of creams, for example, petrolatum-based^{91,105} olive oil-lanolin cream,¹⁰⁶ facilitated skin barrier development in premature infants who were older than 29 to 30 weeks gestational age at birth. In contrast, a multicenter trial in very premature infants, found nosocomial infection rates to be significantly higher for twice-daily application of a petrolatum ointment versus control among infants from 501 to 750 grams,^{107–109} a finding that was not expected due to previous reports for somewhat older infants.⁹¹ Reports to date indicate that the effects of emollient therapy on infection are mixed and depend upon infant age.

Conclusions

At birth, the full-term neonate has a well-developed epidermal barrier fully competent to execute its primary functions of preventing water loss, segregating the internal and external environments of the organism, preventing systemic penetration of external substances and providing protection against solar (mainly ultraviolet) irradiation. In contrast, premature infants emerge from uterine existence with a partially to nearly non-existent (contingent on gestational age) epidermal barrier.

Paradoxically, in many settings, the first encounter of the neonate with skin cleansing practices will entail removal of the

beneficial and protective layer of vernix. Modern recommendations and guidelines recommend allowing the vernix layer to remain in place at least for some hours post-birth to enable its benefits for skin adaptation to the extrauterine environment.

In the full-term neonate, regimens that use gentle cleansers, mild surfactants, and water are entirely appropriate as neonates and young infants tolerate and respond well to a variety of skin cleansing regimens.^{10,11} Importantly, although gentle skin cleansing regimens are best indicated for neonatal skin, the epidermal barrier at birth is well-equipped to prevent/reduced penetration of most xenobiotics. Systemic toxicity due to use of cleansing ingredients, especially at the low concentrations generally found in infant skin care products, while not a concern that can be completely discarded, is not a high probability risk to infant wellbeing in modern societies.

Of special interest in the care of newborn skin is the diaper region which exists from shortly after birth onward, in an environment that can be more hostile to skin integrity than is the case for undiapered, air-exposed skin. Modern disposable diaper technology successfully has reduced some of the main negative impacts of overhydration, increased pH, friction, and other variables on skin integrity. The main concern in diaper area care is irritant dermatitis. The use of emollients, creams, and other protectants is indicated and beneficial to promote barrier repair if and when a child experiences a diaper rash.

To summarize, the weight of available evidence indicates that newborns are well equipped to respond positively to gentle hygiene care practices such as bathing with age-appropriate liquid cleansers. Similarly, the use of alcohol-free wipes and high absorbency disposable diapers, coupled with effective use of skin protectants such as oils, petrolatum-based ointments, and lotion-containing diapers provide safe, effective, and appropriately gentle approaches to care for the more challenging cleansing environment of the young diapered child.

References

1. Nikolovski J, Stamatias GN, Kollias N, et al. Barrier function and water-holding and transport properties of infant stratum corneum are different from adult and continue to develop through the first year of life. *J Invest Dermatol*. 2008;128:1728-1736.
2. Fluhr JW, Darlenski R, Taieb A, et al. Functional skin adaptation in infancy-almost complete but not fully competent. *Exp Dermatol*. 2010;19:483-492.
3. Stamatias GN, Nikolovski J, Mack MC, et al. Infant skin physiology and development during the first years of life: A review of recent findings based on *in vivo* studies. *Int J Cosmet Sci*. 2011;33:17-24.
4. Darlenski R, Fluhr JW. Influence of skin type, race, sex, and anatomic location on epidermal barrier function. *Clin Dermatol*. 2012;30:269-273.
5. Hoeger PH. Physiology of neonatal skin. In: Irvine AD, Hoeger PH, Yan AC, eds. *Harper's textbook of pediatric dermatology*. Oxford, UK: Wiley-Blackwell; 2011. p. 3.1-3.7.
6. Kelleher MM, O'Carroll M, Gallagher A, et al. Newborn transepidermal water loss values: A reference data set. *Pediatr Dermatol*. 2013;30:712-716.
7. Fluhr JW, Pfisterer S, Gloor M. Direct comparison of skin physiology in children and adults with bioengineering methods. *Pediatr Dermatol*. 2000;17:436-439.

8. Fluhr JW, Darlenski R, Lachmann N, et al. Infant epidermal skin physiology: Adaptation after birth. *Br J Dermatol*. 2012;166:483-490.
9. Kikuchi K, Kobayashi H, O'goshi K, et al. Impairment of skin barrier function is not inherent in atopic dermatitis patients: A prospective study conducted in newborns. *Pediatr Dermatol*. 2006;23:109-113.
10. Blume-Peytavi U, Hauser M, Stamatias GN, et al. Skin care practices for newborns and infants: Review of the clinical evidence for best practices. *Pediatr Dermatol*. 2012;29:1-14.
11. Garcia Bartels N, Scheufele R, Prosch F, et al. Effect of standardized skin care regimens on neonatal skin barrier function in different body areas. *Pediatr Dermatol*. 2010;27:1-8.
12. Lavender T, Bedwell C, O'Brien E, et al. Infant skin-cleansing product versus water: A pilot randomized, assessor-blinded controlled trial. *BMC Pediatr*. 2011;11:35.
13. Fairley JA, Rasmussen JE. Comparison of stratum corneum thickness in children and adults. *J Am Acad Dermatol*. 1983;8:652-654.
14. Holbrook K. Embryogenesis of skin. In: Harper J, Oranje A, Prose NS, eds. *Textbook of pediatric dermatology*. Oxford: Blackwell Science; 2000. p. 3-42.
15. Desmedt B, Brink S, Adam R, et al. Baby care products. In: Barel AO, Paye M, Maibach HI, eds. *Handbook of cosmetic science and technology*. Boca Raton: CRC Press; 2014. p. 483-496.
16. Telojski LS, Morello AP, Mack Correa MC, et al. The infant skin barrier: Can we preserve, protect, and enhance the barrier? *Dermatol Res Pract*. 2012;2012:198789.
17. Cunico RL, Maibach HI, Khan H, et al. Skin barrier properties in the newborn. Transepidermal water loss and carbon dioxide emission rates. *Biol Neonate*. 1977;32:177-182.
18. Yosipovitch G, Maayan-Metzger A, Merlob P, et al. Skin barrier properties in different body areas in neonates. *Pediatrics*. 2000;106:105-108.
19. Visscher MO, Narendran V, Pickens WL, et al. Vernix caseosa in neonatal adaptation. *J Perinatol*. 2005;25:440-446.
20. Pickens WL, Warner RR, Boissy YL, et al. Characterization of vernix caseosa: Water content, morphology, and elemental analysis. *J Invest Dermatol*. 2000;115:875-881.
21. Hardman MJ, Sisi P, Banbury DN, et al. Patterned acquisition of skin barrier function during development. *Development*. 1998;125:1541-1552.
22. Youssef W, Wickett RR, Hoath SB. Surface free energy characterization of vernix caseosa. Potential role in waterproofing the newborn infant. *Skin Res Technol*. 2001;7:10-17.
23. Hoath SB, Pickens WL, Visscher MO. The biology of vernix caseosa. *Int J Cosmet Sci*. 2006;28:319-333.
24. Akinbi HT, Narendran V, Pass AK, et al. Host defense proteins in vernix caseosa and amniotic fluid. *Am J Obstet Gynecol*. 2004;191:2090-2096.
25. Marchini G, Lindow S, Brismar H, et al. The newborn infant is protected by an innate antimicrobial barrier: Peptide antibiotics are present in the skin and vernix caseosa. *Br J Dermatol*. 2002;147:1127-1134.
26. Tollin M, Bergsson G, Kai-Larsen Y, et al. Vernix caseosa as a multicomponent defence system based on polypeptides, lipids and their interactions. *Cell Mol Life Sci*. 2005;62:2390-2399.
27. Yoshio H, Tollin M, Gudmundsson GH, et al. Antimicrobial polypeptides of human vernix caseosa and amniotic fluid: Implications for newborn innate defense. *Pediatr Res*. 2003;53:211-216.
28. Bautista MI, Wickett RR, Visscher MO, et al. Characterization of vernix caseosa as a natural biofilm: Comparison to standard oil-based ointments. *Pediatr Dermatol*. 2000;17:253-260.
29. Barai N. Effect of vernix caseosa on epidermal barrier maturation and repair: Implications in wound healing. [PhD thesis] Cincinnati, OH USA: University of Cincinnati, Pharmacy. 2005. [http://rave.ohiolink.edu/etdc/view?acc_num=ucin1115914411]. Accessed March 13, 2014.
30. Oudshoorn MHM, Rissmann R, van der Coelen D, et al. Development of a murine model to evaluate the effect of vernix caseosa on skin barrier recovery. *Exp Dermatol*. 2009;18:178-184.
31. Visscher MO, Barai N, LaRuffa AA, et al. Epidermal barrier treatments based on vernix caseosa. *Skin Pharmacol Physiol*. 2011;24:322-329.
32. Tansirikongkol A, Wickett RR, Visscher MO, et al. Effect of vernix caseosa on the penetration of chymotryptic enzyme: Potential role in epidermal barrier development. *Pediatr Res*. 2007;62:49-53.
33. Narendran V, Visscher MO, Abril I, et al. Biomarkers of epidermal innate immunity in premature and full-term infants. *Pediatr Res*. 2010;67:382-386.
34. Rissmann R, Groenink HWW, Weerheim AM, et al. New insights into ultrastructure, lipid composition and organization of vernix caseosa. *J Invest Dermatol*. 2006;126:1823-1833.
35. Schürer NY. Implementation of fatty acid carriers to skin irritation and the epidermal barrier. *Contact Dermatitis*. 2002;47:199-205.
36. Darmstadt GL, Mao-Qiang M, Chi E, et al. Impact of topical oils on the skin barrier: Possible implications for neonatal health in developing countries. *Acta Paediatr*. 2002;91:546-554.
37. Newborn care until the first week of life: Clinical practice pocket guide. World Health Organization. http://www.wpro.who.int/immunization/documents/newborncare_final.pdf. [Published 2009. Accessed March 13, 2014].
38. Blank IH. Factors which influence the water content of the stratum corneum. *J Invest Dermatol*. 1952;18:433-440.
39. Gloor M, Bettinger J, Gehring W. Modification of stratum corneum quality by glycerin-containing external ointments. *Hautarzt*. 1998;49:6-9.
40. Giusti F, Martella A, Bertoni L, et al. Skin barrier, hydration, and pH of the skin of infants under 2 years of age. *Pediatr Dermatol*. 2001;18:93-96.
41. Visscher MO, Maganti S, Munson KA, et al. Early adaptation of human skin following birth: A biophysical assessment. *Skin Res Technol*. 1999;5:213-220.
42. Minami-Hori M, Honma M, Fujii M, et al. Developmental alterations of physical properties and components of neonatal-infantile stratum corneum of upper thighs and diaper-covered buttocks during the 1st year of life. *J Dermatol Sci*. 2014;73:67-73.
43. Saijo S, Tagami H. Dry skin of newborn infants: Functional analysis of the stratum corneum. *Pediatr Dermatol*. 1991;8:155-159.
44. Visscher MO, Chatterjee R, Munson KA, et al. Changes in diapered and nondiapered infant skin over the first month of life. *Pediatr Dermatol*. 2000;17:45-51.
45. Warner RR, Stone KJ, Boissy YL. Hydration disrupts human stratum corneum ultrastructure. *J Invest Dermatol*. 2003;120:275-284.
46. Sato J, Denda M, Chang S, et al. Abrupt decreases in environmental humidity induce abnormalities in permeability barrier homeostasis. *J Invest Dermatol*. 2002;119:900-904.
47. Robinson M, Visscher M, Laruffa A, et al. Natural moisturizing factors (NMF) in the stratum corneum (SC). I. Effects of lipid extraction and soaking. *J Cosmet Sci*. 2010;61:13-22.
48. Visscher MO, Chatterjee R, Ebel JP, et al. Biomedical assessment and instrumental evaluation of healthy infant skin. *Pediatr Dermatol*. 2002;19:473-481.
49. Scott IR, Harding CR. Filaggrin breakdown to water binding compounds during development of the rat stratum corneum is controlled by the water activity of the environment. *Dev Biol*. 1986;115:84-92.
50. Visscher M. Infant skin research. Second Annual Joint Meeting of the International Society of Bioengineering and the Skin and the International Society for Skin Imaging; 2005; Philadelphia, PA; 2005.
51. Visscher MO, Utturkar R, Pickens WL, et al. Neonatal skin maturation—vernix caseosa and free amino acids. *Pediatr Dermatol*. 2011;28:122-132.
52. Rippe F, Schreiner V, Schwanitz H. The acidic milieu of the horny layer: new findings on the physiology and pathophysiology of skin pH. *Am J Clin Dermatol*. 2002;3:261-272.
53. Schmid-Wendtner M, Korting HC. The pH of the skin surface and its impact on the barrier function. *Skin Pharmacol Physiol*. 2006;19:296-302.
54. Aly R, Shirley C, Cunico B, et al. Effect of prolonged occlusion on the microbial flora, pH, carbon dioxide and transepidermal water loss on human skin. *J Invest Dermatol*. 1978;71:378-381.
55. Fluhr JW, Kao J, Jain M, et al. Generation of free fatty acids from phospholipids regulates stratum corneum acidification and integrity. *J Invest Dermatol*. 2001;117:44-51.

56. Puhvel SM, Reischer RM, Amirian DA. Quantification of bacteria in isolated pilosebaceous follicles in normal skin. *J Invest Dermatol.* 1975;65:525-531.
57. Hoeger PH, Enzmann CC. Skin physiology of the neonate and young infant: a prospective study of functional skin parameters during early infancy. *Pediatr Dermatol.* 2002;19:256-262.
58. Fluhr JW, Man M, Hachem J, et al. Topical peroxisome proliferator activated receptor activators accelerate postnatal stratum corneum acidification. *J Invest Dermatol.* 2009;129:365-374.
59. Hachem J, Roelandt T, Schürer N, et al. Acute acidification of stratum corneum membrane domains using polyhydroxyl acids improves lipid processing and inhibits degradation of corneodesmosomes. *J Invest Dermatol.* 2010;130:500-510.
60. Hatano Y, Man M, Uchida Y, et al. Maintenance of an acidic stratum corneum prevents emergence of murine atopic dermatitis. *J Invest Dermatol.* 2009;129:1824-1835.
61. Walker VP, Akinbi HT, Meinzen-Derr J, et al. Host defense proteins on the surface of neonatal skin: Implications for innate immunity. *J Pediatr.* 2008;152:777-781.
62. Cartlidge P. The epidermal barrier. *Semin Neonatol.* 2000;5:273-280.
63. Evans NJ, Rutter N. Development of the epidermis in the newborn. *Biol Neonate.* 1986;49:74-80.
64. Eichenfield LF, Hardaway CA. Neonatal dermatology. *Curr Opin Pediatr.* 1999;11:471-474.
65. Harpin VA, Rutter N. Barrier properties of the newborn infant's skin. *J Pediatr.* 1983;102:419-425.
66. Okah FA, Wickett RR, Pickens WL, et al. Surface electrical capacitance as a noninvasive bedside measure of epidermal barrier maturation in the newborn infant. *Pediatrics.* 1995;96:688-692.
67. Agren J, Sjörs G, Sedin G. Ambient humidity influences the rate of skin barrier maturation in extremely preterm infants. *J Pediatr.* 2006;148:613-617.
68. Sedin G, Hammarlund K, Strömberg B. Transepidermal water loss in full-term and pre-term infants. *Acta Paediatr Scand Suppl.* 1983;305:27-31.
69. Denda M, Sato J, Tsuchiya T, et al. Low humidity stimulates epidermal DNA synthesis and amplifies the hyperproliferative response to barrier disruption: Implication for seasonal exacerbations of inflammatory dermatoses. *J Invest Dermatol.* 1998;111:873-878.
70. Agren J, Sjörs G, Sedin G. Transepidermal water loss in infants born at 24 and 25 weeks of gestation. *Acta Paediatr.* 1998;87:1185-1190.
71. Kalia YN, Nonato LB, Lund CH, et al. Development of skin barrier function in premature infants. *J Invest Dermatol.* 1998;111:320-326.
72. Nonato LB, Lund CH, Kalia YN, et al. Transepidermal water loss in 24 and 25 weeks gestational age infants. *Acta Paediatr.* 2000;89:747-748.
73. Visscher M, Odio M, Taylor T, et al. Skin care in the NICU patient: Effects of wipes versus cloth and water on stratum corneum integrity. *Neonatology.* 2009;96:226-234.
74. Rawlings AV, Scott IR, Harding CR, et al. Stratum corneum moisturization at the molecular level. *J Invest Dermatol.* 1994;103:731-741.
75. Kearns GL. Impact of developmental pharmacology on pediatric study design: Overcoming the challenges. *J Allergy Clin Immunol.* 2000;106:S128-S138.
76. Koren G. Therapeutic drug monitoring principles in the neonate. National Academy of Clinical Biochemistry. *Clin Chem.* 1997;43:222-227.
77. Odio MR, O'Connor RJ, Sarbaugh F, et al. Continuous topical administration of a petrolatum formulation by a novel disposable diaper. 1. Effect on skin surface microtopography. *Dermatology.* 2000;200:232-237.
78. Odio MR, O'Connor RJ, Sarbaugh F, et al. Continuous topical administration of a petrolatum formulation by a novel disposable diaper. 2. Effect on skin condition. *Dermatology.* 2000;200:238-243.
79. Odio M, Friedlander SF. Diaper dermatitis and advances in diaper technology. *Curr Opin Pediatr.* 2000;12:342-346.
80. Smith WJ, Jacob SE. The role of allergic contact dermatitis in diaper dermatitis. *Pediatr Dermatol.* 2009;26:369-370.
81. West DP, Worobec S, Solomon LM. Pharmacology and toxicology of infant skin. *J Invest Dermatol.* 1981;76:147-150.
82. Adam R. Skin care of the diaper area. *Pediatr Dermatol.* 2008;25:427-433.
83. Atherton DJ. A review of the pathophysiology, prevention and treatment of irritant diaper dermatitis. *Curr Med Res Opin.* 2004;20:645-649.
84. Ehretsmann C, Schaefer P, Adam R. Cutaneous tolerance of baby wipes by infants with atopic dermatitis, and comparison of the mildness of baby wipe and water in infant skin. *J Eur Acad Dermatol Venereol.* 2001;15(Suppl 1):16-21.
85. Lodén M, Buraczewska I, Edlund F. The irritation potential and reservoir effect of mild soaps. *Contact Dermatitis.* 2003;49:91-96.
86. Atherton DJ. The aetiology and management of irritant diaper dermatitis. *J Eur Acad Dermatol Venereol.* 2001;15(Suppl 1):1-4.
87. Wiesemann F, Adam R. Absorbent products for personal health care and hygiene. In: Bartels VT, ed. Handbook of medical textiles. Oxford: Woodhead Publishing, Ltd; 2011. p. 316-335.
88. Erasala G, Merlay I, Romain C. Evolution of disposable diapers and reduction of diaper dermatitis. *Arch Pediatr.* 2007;14:495-500.
89. Runeman B. Skin interaction with absorbent hygiene products. *Clin Dermatol.* 2008;26:45-51.
90. Visscher MO, Hoath SB. Diaper dermatitis. In: Chew A, Maibach H, eds. Irritant dermatitis. Berlin: Springer; 2006. p. 37-51.
91. Nopper AJ, Horii KA, Sookdeo-Drost S, et al. Topical ointment therapy benefits premature infants. *J Pediatr.* 1996;128:660-669.
92. Akin F, Spraker M, Aly R, et al. Effects of breathable disposable diapers: Reduced prevalence of Candida and common diaper dermatitis. *Pediatr Dermatol.* 2001;18:282-290.
93. Berg RW. Etiology and pathophysiology of diaper dermatitis. *Adv Dermatol.* 1988;3:75-98.
94. Berg RW, Milligan MC, Sarbaugh FC. Association of skin wetness and pH with diaper dermatitis. *Pediatr Dermatol.* 1994;11:18-20.
95. Garcia Bartels N, Massoudy L, Scheufele R, et al. Standardized diaper care regimen: A prospective, randomized pilot study on skin barrier function and epidermal IL-1 α in newborns. *Pediatr Dermatol.* 2012;29:270-276.
96. Stamatas GN, Zerweck C, Grove G, et al. Documentation of impaired epidermal barrier in mild and moderate diaper dermatitis *in vivo* using noninvasive methods. *Pediatr Dermatol.* 2011;28:99-107.
97. Andersen PH, Bucher AP, Saeed I, et al. Faecal enzymes: *in vivo* human skin irritation. *Contact Dermatitis.* 1994;30:152-158.
98. Adam R, Schnetz B, Mathey P, et al. Clinical demonstration of skin mildness and suitability for sensitive infant skin of a new baby wipe. *Pediatr Dermatol.* 2009;26:506-513.
99. Odio M, Streicher-Scott J, Hansen RC. Disposable baby wipes: Efficacy and skin mildness. *Dermatol Nurs.* 2001;13:107-112.
100. Atherton D. Maintaining healthy skin in infancy using prevention of irritant napkin dermatitis as a model. *Community Pract.* 2005;78:255-257.
101. Visscher MO. Recent advances in diaper dermatitis: Etiology and treatment. *Pediatr Health.* 2009;3:81-98.
102. Schunck M, Neumann C, Proksch E. Artificial barrier repair in wounds by semi-occlusive foils reduced wound contraction and enhanced cell migration and reepithelization in mouse skin. *J Invest Dermatol.* 2005;125:1063-1071.
103. Visscher M, Hoath SB, Conroy E, et al. Effect of semipermeable membranes on skin barrier repair following tape stripping. *Arch Dermatol Res.* 2001;293:491-499.
104. Darmstadt GL, Saha SK, Ahmed ASMNU, et al. Effect of topical treatment with skin barrier-enhancing emollients on nosocomial infections in preterm infants in Bangladesh: A randomised controlled trial. *Lancet.* 2005;365:1039-1045.
105. Lane AT, Drost SS. Effects of repeated application of emollient cream to premature neonates' skin. *Pediatrics.* 1993;92:415-419.
106. Kiechl-Kohlendorfer U, Berger C, Inzinger R. The effect of daily treatment with an olive oil/lanolin emollient on skin integrity in

- preterm infants: A randomized controlled trial. *Pediatr Dermatol*. 2008;25:174-178.
107. Campbell JR, Zaccaria E, Baker CJ. Systemic candidiasis in extremely low birth weight infants receiving topical petrolatum ointment for skin care: A case-control study. *Pediatrics*. 2000;105:1041-1045.
108. Conner JM, Soll RF, Edwards WH. Topical ointment for preventing infection in preterm infants. *Cochrane Database Syst Rev*. 2004: CD001150.
109. Edwards WH, Conner JM, Soll RF. The effect of prophylactic ointment therapy on nosocomial sepsis rates and skin integrity in infants with birth weights of 501 to 1000 g. *Pediatrics*. 2004;113:1195-1203.