

Sarcoidosis: A comprehensive review and update for the dermatologist

Part I. Cutaneous disease

Adele Haimovic, BA,^a Miguel Sanchez, MD,^a Marc A. Judson, MD,^b and Stephen Prystowsky, MD^a
New York and Albany, New York

CME INSTRUCTIONS

The following is a journal-based CME activity presented by the American Academy of Dermatology and is made up of four phases:

1. Reading of the CME Information (delineated below)
2. Reading of the Source Article
3. Achievement of a 70% or higher on the online Case-based Post Test
4. Completion of the Journal CME Evaluation

CME INFORMATION AND DISCLOSURES

Statement of Need:

The American Academy of Dermatology bases its CME activities on the Academy's core curriculum, identified professional practice gaps, the educational needs which underlie these gaps, and emerging clinical research findings. Learners should reflect upon clinical and scientific information presented in the article and determine the need for further study.

Target Audience:

Dermatologists and others involved in the delivery of dermatologic care.

Accreditation

The American Academy of Dermatology is accredited by the Accreditation Council for Continuing Medical Education to provide continuing medical education for physicians.

AMA PRA Credit Designation

The American Academy of Dermatology designates this journal-based CME activity for a maximum of 1 *AMA PRA Category 1 Credits*SM. Physicians should claim only the credit commensurate with the extent of their participation in the activity.

AAD Recognized Credit

This journal-based CME activity is recognized by the American Academy of Dermatology for 1 AAD Credit and may be used toward the American Academy of Dermatology's Continuing Medical Education Award.

Disclaimer:

The American Academy of Dermatology is not responsible for statements made by the author(s). Statements or opinions expressed in this activity reflect the views of the author(s) and do not reflect the official policy of the American Academy of Dermatology. The information provided in this CME activity is for continuing education purposes only and is not meant to substitute for the independent medical judgment of a healthcare provider relative to the diagnostic, management and treatment options of a specific patient's medical condition.

Disclosures

Editors

The editors involved with this CME activity and all content validation/peer reviewers of this journal-based CME activity have reported no relevant financial relationships with commercial interest(s).

Authors

The authors of this journal-based CME activity have reported no relevant financial relationships with commercial interest(s).

Planners

The planners involved with this journal-based CME activity have reported no relevant financial relationships with commercial interest(s). The editorial and education staff involved with this journal-based CME activity have reported no relevant financial relationships with commercial interest(s).

Resolution of Conflicts of Interest

In accordance with the ACCME Standards for Commercial Support of CME, the American Academy of Dermatology has implemented mechanisms, prior to the planning and implementation of this Journal-based CME activity, to identify and mitigate conflicts of interest for all individuals in a position to control the content of this Journal-based CME activity.

Learning Objectives

After completing this learning activity, the participants should be able to recognize the heterogeneous presentations of cutaneous sarcoidosis; discuss the epidemiology of sarcoidosis and possible etiologic agents; and appropriately treat cutaneous sarcoidosis.

Date of release: May 2012

Expiration date: May 2015

© 2012 by the American Academy of Dermatology, Inc.
 doi:10.1016/j.jaad.2011.11.965

Technical requirements:

American Academy of Dermatology:

- Supported browsers: FireFox (3 and higher), Google Chrome (5 and higher), Internet Explorer (7 and higher), Safari (5 and higher), Opera (10 and higher).
- JavaScript needs to be enabled.

Elsevier:

Technical Requirements

This website can be viewed on a PC or Mac. We recommend a minimum of:

- PC: Windows NT, Windows 2000, Windows ME, or Windows XP
- Mac: OS X
- 128MB RAM
- Processor speed of 500MHz or higher
- 800x600 color monitor
- Video or graphics card
- Sound card and speakers

Provider Contact Information:

American Academy of Dermatology
 Phone: Toll-free: (866) 503-SKIN (7546); International: (847) 240-1280
 Fax: (847) 240-1859
 Mail: P.O. Box 4014; Schaumburg, IL 60168

Confidentiality Statement:

American Academy of Dermatology: POLICY ON PRIVACY AND CONFIDENTIALITY

Privacy Policy - The American Academy of Dermatology (the Academy) is committed to maintaining the privacy of the personal information of visitors to its sites. Our policies are designed to disclose the information collected and how it will be used. This policy applies solely to the information provided while visiting this website. The terms of the privacy policy do not govern personal information furnished through any means other than this website (such as by telephone or mail).

E-mail Addresses and Other Personal Information - Personal information such as postal and e-mail address may be used internally for maintaining member records, marketing purposes, and alerting customers or members of additional services available. Phone numbers may also be used by the Academy when questions about products or services ordered arise. The Academy will not reveal any information about an individual user to third parties except to comply with applicable laws or valid legal processes.

Cookies - A cookie is a small file stored on the site user's computer or Web server and is used to aid Web navigation. Session cookies are temporary files created when a user signs in on the website or uses the personalized features (such as keeping track of items in the shopping cart). Session cookies are removed when a user logs off or when the browser is closed. Persistent cookies are permanent files and must be deleted manually. Tracking or other information collected from persistent cookies or any session cookie is used strictly for the user's efficient navigation of the site.

Links - This site may contain links to other sites. The Academy is not responsible for the privacy practices or the content of such websites.

Children - This website is not designed or intended to attract children under the age of 13. The Academy does not collect personal information from anyone it knows is under the age of 13.

Elsevier: http://www.elsevier.com/wps/find/privacypolicy.cws_home/privacypolicy

Sarcoidosis is a common systemic, noncaseating granulomatous disease of unknown etiology. The development of sarcoidosis has been associated with a number of environmental factors and genes. Cutaneous sarcoidosis, the “great imitator,” can baffle clinicians because of its diverse manifestations and its ability to resemble both common and rare cutaneous diseases. Depending on the type, location, and distribution of the lesions, treatment can prevent functional impairment, symptomatic distress, scarring, and disfigurement. Numerous therapeutic options are available for the treatment of cutaneous sarcoidosis, but there are few well designed trials to guide practitioners on evidence-based, best practice management. In part I, we review the current knowledge and advances in the epidemiology, etiology, pathogenesis, and genetics of sarcoidosis, discuss the heterogeneous manifestations of cutaneous sarcoidosis, and provide a guide for treatment of cutaneous sarcoidosis. (J Am Acad Dermatol 2012;66:699.e1-18.)

Sarcoidosis is a multiorgan disease that is characterized by the presence of noncaseating granulomas. While numerous organs may be involved, the lungs, lymph nodes, and skin are most commonly affected. It is suspected that exposure to one or more extrinsic antigens in a genetically susceptible individual leads to the overactivation of inflammatory pathways that promote the formation of sarcoid granulomas. Studies have found an elevated risk of sarcoidosis in individuals who have been exposed to microbial agents^{1,2} and environmental substances.^{3,4} Disease susceptibility may be genetically determined, and several genes that affect the prevalence and course of sarcoidosis have been identified. Specifically, human leukocyte antigen (HLA) genes have been shown to influence the development and progression of sarcoidosis. Skin lesions are present in at least 20% of sarcoidosis cases⁵⁻⁷ and are the initial disease manifestation in nearly one third of these.⁸ However, because sarcoidosis is a multiorgan disease, cutaneous involvement usually does not occur in isolation. Pulmonary involvement occurs in 90% to 95% of cases.^{9,10} Therefore, patients with cutaneous sarcoidosis require an evaluation of symptoms that may be caused by extracutaneous disease.

From the Department of Dermatology,^a New York University School of Medicine, and the Division of Pulmonary and Critical Care Medicine,^b Albany Medical College, Albany.

Dr Judson has received grant support from Celgene, Centocor, and Gilead. Ms Haimovic and Drs Sanchez and Prystowsky have no conflicts of interest to declare.

EPIDEMIOLOGY

Key points

- **African Americans and women have higher rates of sarcoidosis**
- **Disease onset peaks during the third and fourth decades of life**
- **Severity and extra-thoracic involvement vary among races and ethnicities**

CAPSULE SUMMARY

- Sarcoidosis is a multisystemic, inflammatory disease of unknown etiology that is characterized by noncaseating granulomas.
- Studies indicate that the disease is associated with genetic and immune factors as well as certain exposures.
- Skin manifestations are divided into specific lesions with histopathologically evident noncaseating granulomas, and nonspecific lesions that develop as a result of a reactive process that does not form granulomas.
- Standard therapy includes corticosteroids, methotrexate, antimalarials, tetracyclines and tumor necrosis factor- α inhibitors for recalcitrant cases.

The prevalence of sarcoidosis varies by geographic location, race, and gender. In the United States, the disease prevalence is estimated to be between 10 to 40 cases per 100,000 persons,¹¹ with a much higher annual incidence in African Americans (35.5-64 cases/100,000 population) than in whites (10.9-14 cases/100,000 population).^{12,13} Scandinavia has the world's highest prevalence of reported cases (50-60 cases/100,000 population),¹⁴ whereas the annual incidence in Japan is only one to two cases per 100,000 population.¹⁵

The onset of sarcoidosis peaks during the third and fourth decade of life in the general population¹² and during the fourth decade of life in African Americans.¹⁶ The incidence is higher in women than in men.¹⁷ In Scandinavian and Japanese women, there is a bimodal age of onset, with peaks at 25 to 29 and 65 to 69 years of age in Scandinavian women¹⁸

Funding sources: None.

Reprint requests: Stephen Prystowsky, MD, Department of Dermatology, New York University School of Medicine, 550 First Ave, New York, NY 10016. E-mail: steveprystowmd@aol.com.

0190-9622/\$36.00

Abbreviations used:

APC:	antigen-presenting cell
EN:	erythema nodosum
HLA:	human leukocyte antigen
IL:	interleukin
TNF- α :	tumor necrosis factor—alfa

and 25 to 39 and 50 to 69 years of age in Japanese women.^{19,20}

The phenotypic expression of sarcoidosis varies between races and ethnicities.²¹ Compared to whites, African Americans have a more severe and rapidly progressive disease course.^{12,22} In the United States, African Americans develop extrathoracic organ involvement more often than whites ($\chi^2 = 24.32$; $P < .001$).¹⁰ Chronic skin lesions, such as lupus pernio, plaques, nodules, and nail dystrophy, are also more common in African Americans.²³ About half of Japanese patients present with ocular involvement,²³ in contrast to only 10% of sarcoidosis patients from other ethnic groups. Japanese patients also have the highest rate of cardiac sarcoidosis, which is the leading cause of disease mortality in this population.²³ Scandinavians present with erythema nodosum (EN) more often than any other group.²³

PATHOGENESIS, ETIOLOGY, AND GENETICS

Key points

- Sarcoidosis is characterized by noncaseating granulomas within the involved organs
- Granulomas resolve in 60% of sarcoidosis cases; however, the disease progresses to fibrosis in some patients
- The complex interaction between antigens, genetic factors, and the immune response is believed to influence host susceptibility to sarcoidosis
- The etiology remains unknown, but environmental exposures and infectious agents have been suspected
- Studies of human leukocyte antigen genes and other genes, many of which are involved in the induction of immune responses, have been associated with variations in sarcoidosis susceptibility and prognosis

The classic pathologic finding of sarcoidosis is a noncaseating granuloma consisting of centrally organized collections of macrophages and epithelioid cells encircled by lymphocytes. Extrinsic antigens potentially trigger a dysregulated type 1 helper T cell immune response that generates the formation of noncaseating granulomas. In more than 60%

Table I. Etiologic agents associated with sarcoidosis

Environmental and occupational	Infectious
Mildew	Mycobacteria
Mold	<i>Propionibacterium acnes</i>
Insecticides	Viruses (herpes, Coxsackie B, cytomegalovirus, retrovirus, and Epstein—Barr)
Combustible wood	
Firefighting	
Building materials	<i>Borrelia burgdorferi</i>
Industrial organic dusts	Mycoplasma
	Chlamydia

of patients with sarcoidosis, the granulomatous changes resolve without residua within 2 to 5 years.²⁴ However, the disease is chronic or progresses to fibrosis in 10% to 30% of cases.²⁵ The development of fibrosis causes permanent tissue damage, whereas granulomatous inflammation without fibrosis is potentially reversible. Factors that trigger the formation of fibrosis in sarcoidosis are poorly understood.

Although the immunopathogenesis of sarcoidosis remains unknown, an interplay between extrinsic antigens and an individual's immunogenetic response is believed to trigger the development and progression of the disease.^{26,27} The putative antigen(s) is unknown, but may be derived from a persistent infectious organism or an agent associated with an environmental or occupational exposure (Table I).^{1,3,24-26,28-30} Mycobacteria have long been implicated as etiologic agents. Using sensitive laboratory techniques, investigators have detected mycobacteria in sarcoid lesions but not in nonsarcoid control tissue,^{2,31,32} and recent studies support a role for mycobacteria in at least some cases of sarcoidosis.¹ Many other infectious and noninfectious exposures have been associated with the disease. It may be that numerous antigens may cause sarcoidosis depending on the individual's immune constitution. This may account for the protean manifestations and spectrum of the disease severity. Other infectious agents that have been associated with sarcoidosis in previous reports include *Propionibacterium acnes*, Epstein—Barr virus, and herpesvirus.²⁶ Reported noninfectious exposures associated with sarcoidosis have included World Trade Center disaster dust,³³ metals, combustible wood products, and moldy environments.^{3,24,28,29}

The initial step in the formation of a sarcoidal granuloma is the recognition and phagocytosis of a putative agent by an antigen-presenting cell (APC). The presentation of nondegradable, immunogenic particles by the APC to a CD4⁺ T cell elicits a cellular

Table II. Cutaneous sarcoidosis

Variants of cutaneous sarcoidosis	Frequency	Association with systemic sarcoidosis*
Papular	Very common	Acute form of sarcoidosis (hilar lymphadenopathy, acute uveitis, and peripheral lymph node enlargement) that often disappears within 2 years ^{5,51}
Plaque	Very common	Chronic disease course ^{46,51} and more systemic extrathoracic involvement ⁵
Lupus pernio	Common	Often found in patients with chronic progressive systemic sarcoidosis with both severe pulmonary and extrathoracic involvement ^{51,56,78,156}
Psoriasiform	Uncommon	
Annular	Uncommon	
Lichenoid	Rare	Most frequently reported in young children who presented with eye and joint complications and no respiratory involvement ^{157,158}
Photodistributed	Rare	
Verrucous	Rare	Reports in patients with systemic involvement, particularly significant pulmonary disease ¹⁵⁹
Ichthyosiform	Rare	In one study, 95% of patients with ichthyosiform sarcoidosis developed systemic disease ^{60,160}
Lymphedematous	Rare	
Subcutaneous	Common	Increased incidence of systemic involvement has been shown in a number of studies ^{5,73,74,161}
Tumoral	Rare	
Scar	Common	Controversial reports have suggested an increased incidence of systemic involvement (pulmonary involvement, bone cysts, lymphadenopathy, uveitis, and parotid enlargement), ⁷⁹ while others have reported isolated cutaneous disease ⁸⁰
Atrophic	Uncommon	
Ulcerative	Uncommon	Associated with sarcoidal involvement of multiple organs ⁶⁸
Hypopigmented	Uncommon	
Erythrodermic	Rare	Case reports have been in individuals with systemic disease. Symptoms such as fever, weight loss, arthralgias, uveitis, and dyspnea have been reported ¹⁶²
Angiolupoid	Uncommon	
Sarcoidal alopecia	Rare	In the documented cases, almost all patients have evidence of systemic disease ¹⁶³
Polymorphous	Rare	Frequently associated with multisystemic sarcoidosis ⁷⁰
Nail	Rare	Associated with chronic sarcoidosis ¹⁶⁴
Mucousal	Uncommon	
Erythema nodosum	Very common	Acute and benign disease, likely to have a favorable prognosis with >80% complete resolution within 2 years ⁸⁸

*The relationship between a specific cutaneous lesion and systemic sarcoidosis is not fully understood. However, associations between specific lesions and various organ involvement or disease course have been suggested.

immune response with secretion of cytokines (tumor necrosis factor— α [TNF- α], interleukin [IL]-12, IL-15, and IL-18, and macrophage inflammatory protein 1) that generate granulomatous inflammation within target organs.³⁴ The efficiency of antigen processing, antigen presentation, and cytokine release is probably genetically determined and influences the susceptibility to and phenotypic presentation of sarcoidosis.^{20,35}

Evidence supporting the influence of genetics in the pathogenesis of sarcoidosis emanates from familial clustering of cases,³⁶⁻³⁸ altered susceptibility and disease severity in various racial groups,¹² and the increased incidence of sarcoidosis in monozygotic twins compared to dizygotic twins.³⁹

The expression of candidate genes, many of which regulate processes involved in the pathogenesis of

sarcoidal granulomas, has been associated with variations in sarcoidosis susceptibility and prognosis.³⁶ The most widely studied genes have been those constituting the HLA system.³⁶ Studies have correlated different HLA phenotypes with specific manifestations and with the severity of sarcoidosis.^{36,40,41} The integral role of HLAs in antigen presentation, cytokine production, and granuloma formation⁴² offers a rationale for the variation in disease susceptibility and prognosis associated with specific HLA phenotypes. In addition to candidate gene studies, genome scans have been used to compare afflicted and healthy relatives and identify the chromosomal regions with gene variants that are present only in sarcoidosis patients.^{43,44} However, genetic research in sarcoidosis is particularly challenging because

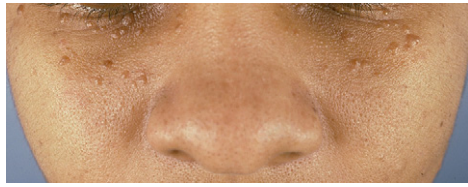


Fig 1. Smooth surfaced, skin-colored, granulomatous papules on a woman with papular sarcoidosis. The lesions resemble syringomas but, depending on the distribution and size, may be clinically misdiagnosed as other adnexal or cutaneous neoplasms.

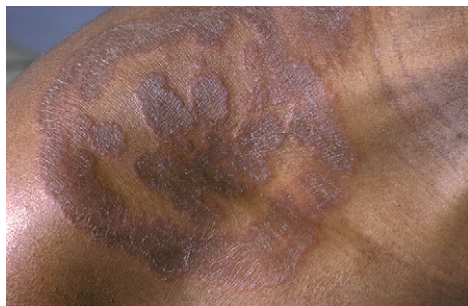

Fig 2. Annular sarcoidosis may be misdiagnosed as a dermatophyte infection, although scaling is not usually present in the former.

interactions between multiple genes may be involved³⁶; as previously implied, sarcoidosis may consist of several granulomatous diseases (“the sarcoidoses”),³⁶ each with its own putative exposure and genetic association.

CUTANEOUS DISEASE

Key points

- **The risk of severe systemic involvement may vary according to the type of skin lesion**
- **Lupus pernio can produce considerable disfigurement, is associated with chronic and systemic disease, and can be therapeutically challenging**
- **Erythema nodosum, the most common type of nonspecific lesion, has a favorable prognosis**

Eruptions caused by sarcoidosis are classified as “specific” (noncaseating granulomas are present in biopsy specimens of tissue) or “nonspecific” (lesions develop as a result of a reactive process without the formation of granulomas).⁴⁵ Specific lesions, listed in Table II, develop in 9% to 15% of all sarcoidosis patients.⁴⁵ These lesions have highly variable manifestations and can mimic many skin diseases (Figs 1 and 2).

Papular sarcoidosis is often present on the face, especially around the eyelids and nasolabial folds.⁴⁶ This type of eruption is associated with a favorable disease prognosis, and the lesions usually resolve

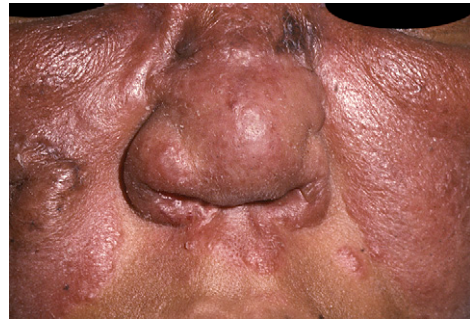

Fig 3. Advanced lupus pernio with bilateral, symmetric, indurated, sharply demarcated, brownish-red plaques confluent across the malar, submalar, and infraorbital areas and the nose. Some areas within the right cheek are nodular. There is a bulbous nasal deformity and involvement of both nares with extension into the nasal mucosa and partial destruction of the left nare.

without significant scarring.⁴⁷ Maculopapular eruptions favor the neck, trunk, extremities, and mucous membranes.^{46,48} Acute organ involvement, such as sudden lymphadenopathy, acute arthritis, acute uveitis,⁴⁸ parotid gland enlargement,⁵ and abnormal chest radiographs, have been associated with this type of eruption.⁴⁹ However, the overall prognosis for maculopapular sarcoidosis is favorable, with one study reporting complete resolution of skin lesions in 78% of cases within 2 years.⁵⁰ In contrast, plaque sarcoidosis, which more commonly develops on the back, buttocks, face, and extensor surfaces of the extremities,⁴⁶ is associated with chronic disease,⁵ with one study reporting persistence of sarcoidosis in 93% of cases after 2 years.⁵¹ In the annular variant, circinate or annular papules and/or plaques predominate on the face often on the forehead.⁴⁸ These lesions may heal with permanent scarring and hair loss.⁵² A case with annular plaques and nodules caused by palisaded and neutrophilic granulomatous dermatitis on the legs of a woman with sarcoidosis was recently reported.⁵³

Lupus pernio is characterized by chronic, violaceous to telangiectatic, induration, predominantly on the nose and cheeks.^{54,55} The lesions enlarge and become confluent to form progressively disfiguring nodular plaques on the nose and adjacent cheeks (Fig 3).⁵⁶ In addition, the lesions can involve the upper respiratory tract and cause nasal ulceration, obstruction, and perforation of the nasal septum.^{55,57,58} Some cases have developed plaques on the arms, thighs, and buttocks^{54,56} and sausage-shaped expansion of the phalanges.^{59,60} This form of sarcoidosis can be recalcitrant to systemic corticosteroids and other immunosuppressants and may be an indicator of current or impending organ involvement.⁵⁴ A clinicoradiologic study found

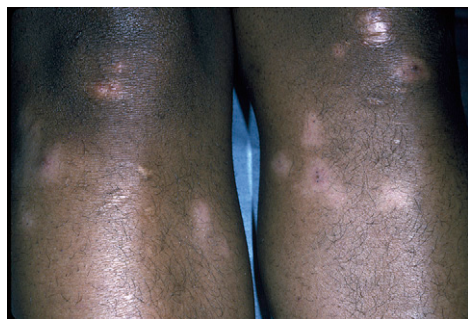

Fig 4. Well-demarcated leukodermic patches, typical of hypopigmented sarcoidosis. The differential diagnosis includes hypopigmented cutaneous T-cell lymphoma.

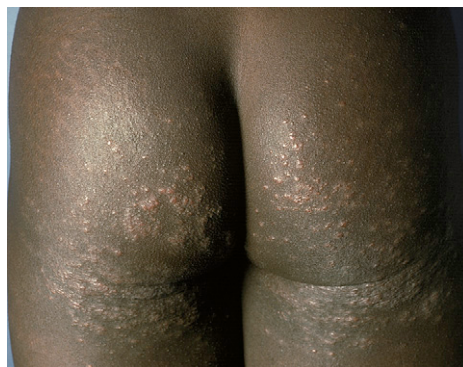

Fig 6. Lichenoid sarcoidosis, a variant of papular sarcoidosis, can mimic lichen planus or lichen planopilaris.

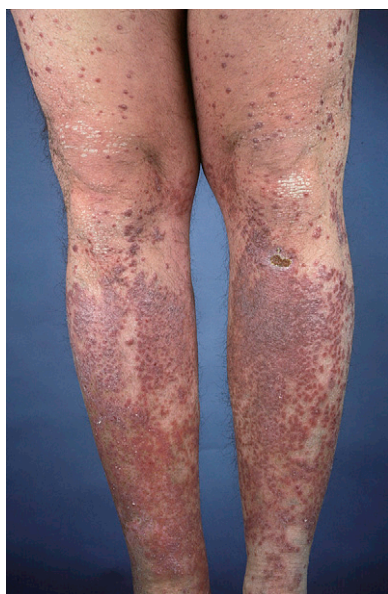

Fig 5. Psoriasiform sarcoidosis with hyperkeratotic plaques on the knees and lower extremities that resemble psoriasis. The appearance of eruptive papules on the thighs and legs is suggestive of guttate psoriasis, and can make the clinical diagnosis of sarcoidosis even more challenging.

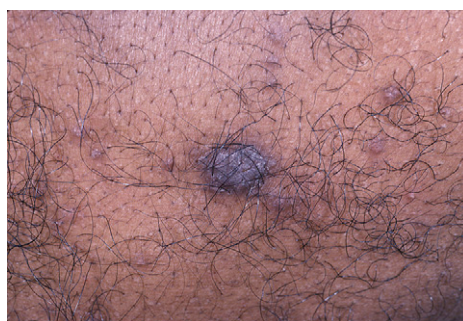

Fig 7. Verrucous sarcoidosis presenting as a hyperkeratotic papule. The lesions may be difficult to clinically distinguish from a wart.

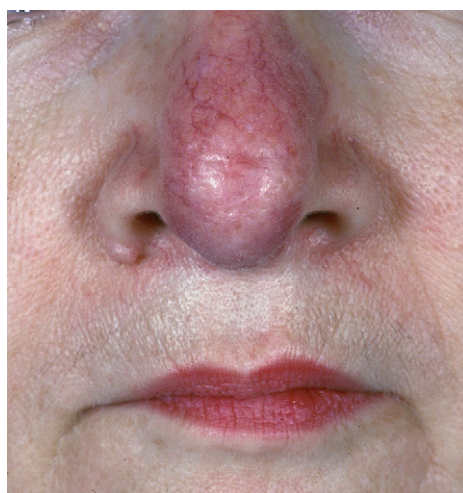

Fig 8. Angiolupoid sarcoidosis with multiple prominent telangiectasias within the lesion.

frequent intrathoracic (74%), upper respiratory tract (54%), ocular (37%), bone cysts (54%), and reticulo-endothelial (54%) involvement in patients with lupus pernio.⁵⁶ Lupus pernio is more common in women. Mutilating sarcoidosis appears to be a severe form of lupus pernio, with large centofacial tumors and extension into the oral and upper respiratory tissue that resemble Wegener granulomatosis and malignant pleomorphic lymphoma.⁶¹

One prospective study of 54 South Africans with skin sarcoidosis found that one quarter of patients presented with hypopigmented (Fig 4), ichthyosiform, lymphedematous, mutilating, ulcerative, verrucous, and other atypical forms.⁶² Psoriasiform (Fig 5), lichenoid (Fig 6), verrucous (Fig 7), and

angiolupoid (Fig 8) are variants of papular or plaque sarcoidosis that can be confused with psoriasis, lichen planus, warts (or lichen simplex chronicus), or lupus erythematosus, respectively.⁶³ The verrucous form is most commonly seen on the face or areas such as the groin and axillae where there is constant friction of the lesions, and in patients with pruritus.⁶⁴

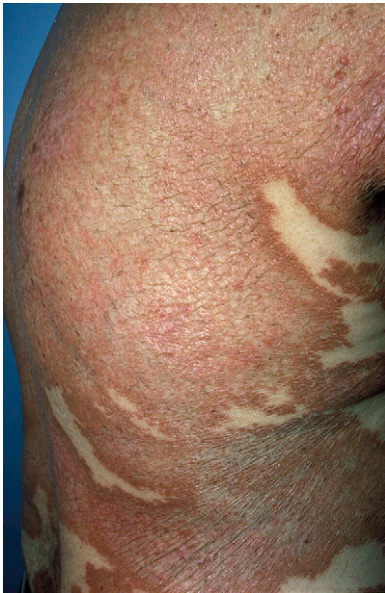

Fig 9. Erythrodermic sarcoidosis is a rare cause of erythroderma.

Atrophic and ulcerative sarcoidosis appear to be clinical extremes of the same disease spectrum, with ulceration developing on an atrophic, or “necrobiosis-like” plaque. Trauma may contribute to the ulceration. The ulcers usually do not heal without topical or systemic immunosuppressive or immunomodulatory therapy, although one case responded to a living bilayered skin graft.⁶⁵ In a retrospective study of 147 cases of cutaneous sarcoidosis, seven cases (5%) had ulcerative sarcoidosis, suggesting that it is more common than the literature suggests, at least in Japanese and African American patients.^{66,67} The suggestion that this type of sarcoidosis is increasing may be related to a greater number of biopsy specimens of nonhealing ulcers in specialized wound care centers.⁶⁷ Because the lesions are often pretibial, the ulcers are often misdiagnosed as venous ulcers despite the usual absence of edema and other signs of venous hypertension. However, sarcoidosis ulcers can develop in the setting of venous insufficiency. In most cases of ulcerative sarcoidosis, systemic disease is present at the onset of skin lesions.⁶⁸ In one study, 95% of patients with ichthyosiform sarcoidosis, a rare form, ultimately developed systemic involvement.^{7,69} Polymorphous sarcoidosis refers to the presence of different types of lesions, both specific and nonspecific, in the same patient. This form is usually associated with multisystem disease.⁷⁰ Hypopigmented sarcoidosis should be included in the differential diagnosis of hypopigmented cutaneous T-cell lymphoma and other leukodermic disorders. Erythrodermic sarcoidosis is rare and seldom considered in the clinical differential of

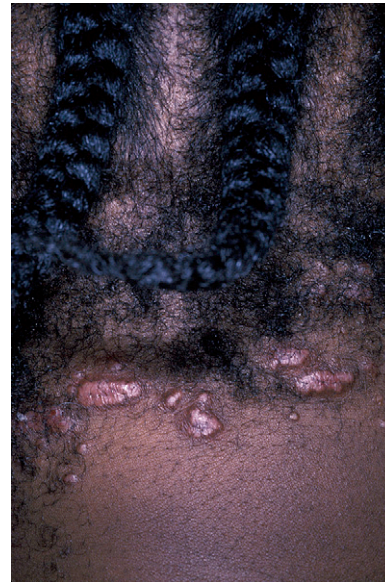

Fig 10. Papular sarcoidosis on the nape of the neck is difficult to distinguish from acne keloidalis nuchae and may represent a form of scar sarcoidosis.

erythrodermas (Fig 9). Notably, the histologic presence of epithelioid granulomas has been reported in some cases of Sézary syndrome with a more indolent than expected course.⁷¹ Photodistributed sarcoidosis is recognized as a rare form of sunlight-induced papular sarcoidosis with negative phototesting that is distinct from polymorphous light eruption and lupus erythematosus.⁷²

In the subcutaneous (Darier–Roussy) form of sarcoidosis, deep 0.5- to 2.0-cm nodules are usually found on the upper extremities⁷ but, when present on the lower extremities, can be differentiated from EN by the absence of tenderness and inflammation. Most studies report an association between subcutaneous sarcoidosis and systemic disease.^{73,74} Tumoral sarcoidosis is rare, but skin tumors as large as 10 cm × 20 cm have been reported on the lumbosacral area.⁷⁵

Scar sarcoidosis is characterized by the infiltration of noncaseating sarcoidal granulomas in surgical scars, tattoos, skin piercings, and other sites of trauma (Fig 10).^{76,77} It may be difficult to clinically distinguish scar sarcoidosis from a granulomatous foreign body reaction in a scar. Some studies suggest that the incidence of pulmonary involvement, bone cysts, lymphadenopathy, uveitis, and parotid enlargement is higher in cases of scar sarcoidosis,^{78,79} but others have described a more propitious prognosis.⁸⁰

Scalp sarcoidosis is rare but can lead to scarring and, less commonly, nonscarring alopecia. Other than the nose, the lips are the most frequently involved mucosal surface, but lesions in the oral cavity (Fig 11)

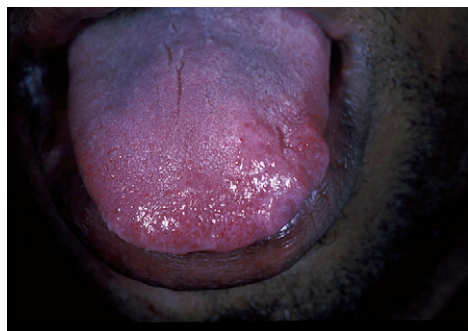

Fig 11. Oral sarcoidosis involving the tongue.

and anogenital area have been reported. Sarcoidosis of the nail can present as subungual hyperkeratosis, clubbing, pitting, trachyonychia, paronychia with nail fold fissuring, pterygium, onycholysis, dactylitis, longitudinal ridging, and discoloration of the nail bed (Fig 12).⁸¹⁻⁸³ Nail involvement is usually a marker of chronic disease.⁸³ Nail dystrophy from sarcoidosis is often accompanied by phalangeal bone disease, which is frequently associated with intrathoracic sarcoidosis.⁸⁴ Conversely, progressive polycystic osteitis with soft tissue involvement (Perthes–Jüngling disease) of the fingers and toes can produce nail dystrophy. A severe form with bulbous swelling of the fingertips, “drumstick dactylitis,” has been associated with lupus pernio.

EN, the most common nonspecific lesion, develops in up to 25% of sarcoidosis cases.⁸⁵ EN has been shown to have prognostic significance in sarcoidosis⁵ and is usually associated with transient disease that does not require therapy.⁴⁷ The triad of EN, acute polyarthritis (often periarticular ankle inflammation), and bilateral hilar lymphadenopathy with or without parenchymal infiltrates, known as Löfgren syndrome, is an acute form of sarcoidosis that is usually self-limiting.⁸⁶ Notably, the presence of all three clinical findings is not required for a diagnosis of Löfgren syndrome. More than 80% of cases of Löfgren syndrome resolve spontaneously within 2 years.^{87,88} Recent genetic studies have suggested that certain HLA-DRB1 alleles affect disease prognosis in Löfgren syndrome.⁸⁹ In one study, 95% of DRB1*03-positive patients—but only 50% of DRB1*03-negative patients—had complete resolution of disease within 2 years.⁸⁹

THERAPY

Key points

- **Treatment for cutaneous sarcoidosis is recommended for disfiguring, cosmetically distressing, and symptomatic disease**
- **Topical or intralesional corticosteroids are the first-line therapy for localized and mild disease limited to the skin**

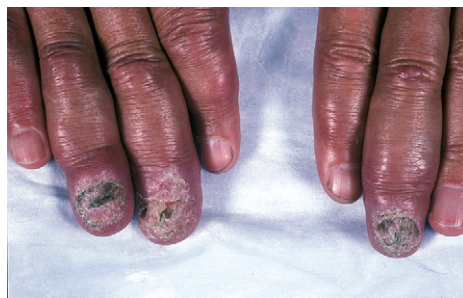

Fig 12. Changes in this case of sarcoidal dactylitis and nail dystrophy include brittleness, onycholysis, and subungual hyperkeratosis.

- **Oral corticosteroids are the drug of choice for rapidly progressive or topical therapy–unresponsive lesions**
- **Anti-inflammatory and immunosuppressive agents are administered as monotherapy or as adjuvants to taper corticosteroids**
- **Tumor necrosis factor–alpha inhibitors have been shown to be beneficial in recalcitrant skin cases**

A comprehensive discussion of the therapeutic management of pulmonary,^{90,91} ocular,⁹² cardiac,⁹³ and neurosarcoidosis⁹⁴ is beyond the scope of this review. Treatment is not necessary for all patients with sarcoidosis, because the disease can remain stable or spontaneously remit, and the extent and effect of organ involvement may not justify the risk of drug-induced complications. However, treatment is recommended for patients with ocular disease, symptomatic cardiac or neurosarcoidosis, unremitting hypercalcemia, progressive pulmonary disease, and any organ involvement that adversely affects quality of life.²⁵

Therapeutic decisions for cutaneous sarcoidosis are often guided by the impact of disfigurement and are limited by comorbidities that increase the risk of drug toxicity. Despite extensive clinical experience with many treatments for cutaneous sarcoidosis, few have been evaluated in blinded, randomized trials (Table III).

Although topical corticosteroids are generally considered to be beneficial for skin lesions, evidence of their efficacy is scant. In one report, the papulonodules of three patients healed without atrophy within 3 to 5 weeks of treatment with clobetasol propionate 0.05% cream applied once a week under polyurethane dressing occlusion.⁹⁵ Halobetasol propionate 0.05% ointment applied twice daily caused flattening but not resolution of lupus pernio papules in another patient.⁹⁶ In other reports that documented clearing of sarcoidosis lesions with topical

Table III. Summary of pharmacologic agents used for treatment of cutaneous sarcoidosis*

Treatment	Usual dose	Indications	Main potential side effects	Level of evidence [†]	Cost [‡]	Reference
Class I ultrapotent topical corticosteroids (clobetasol or halobetasol propionate)	0.05% ointment applied twice weekly or under occlusive dressing, twice weekly	Limited and discrete papules and plaques	Atrophy, striae, telangiectasias, purpura, and acne folliculitis; may use medium potency corticosteroids on areas with thinner skin	IIB	45-g tube, \$25	Volden ⁹⁵ and Khatri et al ⁹⁶
Intralesional triamcinolone	3-10 mg/mL every 3-4 wks until resolution occurs	Limited and discrete papules, plaques, and nodules	Hypopigmentation and atrophy	IIB	\$30 for 50 mg injectable	Callen ⁹⁷ and Verbov ⁹⁸
Oral corticosteroid	Initially, 0.5-1 mg/kg/d (prednisone equivalent); gradually taper to the lowest effective dose (often 10 mg/d) and switch to an every other day schedule	Widespread, disfiguring, chronic, or lesions refractory to local therapy; recalcitrant LP or ulcerative lesions	Short-term mood disturbance, gastrointestinal upset, acne folliculitis, increased appetite, hypertension, diabetes mellitus, weight gain, iatrogenic Cushing syndrome, osteoporosis aseptic vascular necrosis, and psychosis	IIB	\$10-20 monthly	Badgwell and Rosen, ⁹⁹ Veien, ¹⁰⁰ and Russo and Millikan ¹⁰¹
Chloroquine	250-750 mg daily; maximum dose is 3.5 mg/kg/d	Steroid-sparing agent or as monotherapy is effective in all lesions; very effective for LP	Corneal deposits and retinopathy (risk decreases if doses are <3.5 mg/kg/d and no renal disease is present); hepatic necrosis (in patients with porphyria cutanea tarda)	IIB	\$105 monthly for 250 mg	Veien, ¹⁰⁰ Siltzbach and Teirstein, ¹⁰⁵ and Zic et al ¹⁰⁶
Hydroxychloroquine	200-400 mg daily; maximum dose is 6.5 mg/kg/d	Same as for chloroquine	Same as for chloroquine; hydroxychloroquine has less corneal, lenticular, and uveal toxicity than chloroquine (risk of retinopathy decreases if doses are <6.5 mg/kg/d and no renal disease is present)	IIB	\$35 monthly for 200 mg	Veien, ¹⁰⁰ Mosam and Morar, ¹⁰⁷ Jones and Callen, ¹⁶⁵ and Moss et al ¹⁶⁶

Continued

Table III. Cont'd

Treatment	Usual dose	Indications	Main potential side effects	Level of evidence [†]	Cost [‡]	Reference
Methotrexate	7.5-25 mg/wk orally, SQ or IM; maintenance dose may be administered biweekly	Steroid-resistant lesions or patients unable to take steroids; especially useful for ulcerative sarcoidosis	Hepatotoxicity, hypersensitivity pneumonitis, pancytopenia, neutropenia, immunosuppression, dose-dependent mucositis, and nausea; folic acid supplementation may reduce toxicity	IIB	\$24-64 monthly	Rosen, ⁹⁹ Veien, ¹⁰⁰ Baughman and Lower, ^{108,109} Lower and Baughman, ^{111,167} and Webster et al ¹⁶⁸
Tetracycline	Minocycline, 200 mg/d; Tetracycline, 1,000 mg/d	May be helpful in select cases	Phototoxicity, dizziness, gastrointestinal upset, hypersensitivity reactions, vulvovaginal candidiasis, tooth discoloration, and bone deposition; contraindicated for children <8 yrs of age and pregnant women	IIB	Minocycline, \$45 monthly; tetracycline, \$16 monthly	Marshall and Marshall ¹¹² and Bachelez et al ¹¹³
Thalidomide	50-400 mg/d	Refractory skin disease, especially LP	Teratogenicity, peripheral neuropathy, sedation, nausea, neutropenia, and venous thrombosis	IIB	\$8300 monthly for 100 mg/d	Baughman et al, ¹¹⁷ Oliver et al, ¹¹⁸ and Nguyen et al ¹¹⁹
Infliximab	3-7 mg/kg IV at 0, 2, and 6 wks (3-10 mg/kg) and then every 6 wks; dose and interval may be adjusted depending on the response	Widespread disease, severely disfiguring lesions, and refractory lesions	Allergic reactions (including anaphylaxis), reactivation of tuberculous, granulomatous infections, other infections lymphoma, solid organ malignancy, and demyelinating disease	IIB	\$1900 per infusion	Stagaki et al, ¹¹⁴ Doty et al, ¹²⁷ Saleh et al, ¹²⁸ Baughman et al, ¹²⁹ and Meyerle and Shorr ¹⁶⁹

Adalimumab	40 mg every 1-2 wks [§]	Widespread disease, severely disfiguring lesions, and refractory lesions	Headache, nausea, injection site reaction, reactivation of tuberculosis, other infections, lymphoma, solid organ malignancy, and demyelinating disease	III	\$4000 monthly	Heffernan and Smith, ¹²⁰ Philips et al, ¹²¹ and Callejas-Rubio et al ¹⁷⁰
------------	----------------------------------	--	--	-----	----------------	---

IM, Intramuscularly; IV, intravenously; LP, lupus pernio; SQ, subcutaneously.

*Table modified from Lodha et al.⁷

[†]Level IA evidence includes evidence from metaanalysis of randomized controlled trials; level IB evidence includes evidence from at least one randomized controlled trial; level IIA evidence includes evidence from at least one controlled study without randomization; level IIB evidence includes evidence from at least one other type of experimental study; level III evidence includes evidence from nonexperimental descriptive studies, such as comparative studies, correlation studies, and case control studies; level IV evidence includes evidence from expert committee reports or opinions or clinical experience of respected authorities, or both.

[‡]Approximate retail price based upon Internet listings and national pharmacies (www.drugstore.com, Walgreens, and Duane Reade) as of June 2011.

[§]40 mg four times per week may be required for the treatment of cutaneous sarcoidosis.

corticosteroids, the patients were simultaneously treated with systemic medications.

Intralesional injections of triamcinolone acetonide at concentrations of 3 to 20 mg/mL, repeated every 3 to 4 weeks, deliver the corticosteroid to the reticular dermis, and may be more effective than topical preparations.^{97,98} However, topical or intralesional corticosteroids are impractical for cases with widespread lesions.⁹⁹

Systemic corticosteroids remain the treatment of choice for rapidly progressive, generalized, or highly disfiguring skin disease.^{99,100} Once a favorable clinical response is achieved—usually in 1 to 3 months—the initial dose of 20 to 60 mg of prednisone daily⁹⁹ is tapered by 5 to 10 mg per week on alternate days to the lowest dose that prevents disease relapse.⁹⁹⁻¹⁰¹ The improvement of skin lesions can indicate a therapeutic benefit in other organs.^{100,102}

The coadministration of corticosteroid-sparing agents or intralesional and topical corticosteroids appear—but have not been unequivocally proven—to accelerate tapering and achieve lower doses of systemic corticosteroids.⁷ In general, corticosteroid-sparing agents are indicated for patients who require a maintenance dose equivalent to 10 mg of prednisone daily.¹⁰³

Hydroxychloroquine and chloroquine have been among the most commonly prescribed agents for skin sarcoidosis. They have been used as monotherapy or as corticosteroid-sparing agents. However, no randomized, placebo-controlled studies of antimalarial drugs have been conducted to evaluate their efficacy in cutaneous sarcoidosis. A literature review documented improvement in 57 of 78 skin sarcoidosis cases treated with hydroxychloroquine or chloroquine alone.¹⁰⁴ Chloroquine was considered in one report to be more effective at preventing the development of new lesions than at healing existing lesions.¹⁰⁵ An open-label trial found improvement of skin lesions in all 14 patients with cutaneous sarcoidosis treated with chloroquine for 4 to 17 months. Relapses occurred in nine of the 13 patients available for reevaluation after chloroquine was discontinued, suggesting a therapeutically suppressive benefit.¹⁰⁵ Hydroxychloroquine has a lower incidence of retinopathy than chloroquine, but the efficacy data are more robust for chloroquine.^{106,107}

Methotrexate is used predominantly for recalcitrant skin disease or as a corticosteroid-sparing agent.¹⁰⁸ In a review by Baughman and Lower,¹⁰⁹ the response rate of skin lesions to methotrexate was greater than 80%. In an open-label clinical trial of 16 patients with infiltrative cutaneous sarcoidosis, the skin lesions resolved in 12 patients and partially improved in the other four patients during treatment

with oral methotrexate at a dose of 25 mg weekly. The dose was gradually reduced to 5 to 15 mg weekly once a clinical response was achieved.^{100,110} In an interventional study that followed 50 patients treated with methotrexate at a dose of 10 mg weekly for a minimum of 2 years,¹¹¹ 16 of the 17 cases with cutaneous sarcoidosis had a beneficial response to methotrexate alone. In 25 out of the 30 patients with extracutaneous sarcoidosis also treated with prednisone, the corticosteroid dose was decreased or discontinued, confirming methotrexate's role as a steroid-sparing agent. In addition, 35 of the 40 patients who discontinued methotrexate therapy experienced relapse, suggesting that methotrexate is suppressive rather than curative.¹¹¹ Notably, the improvement of skin lesions during methotrexate therapy may be delayed for up to 6 months.¹⁰⁸

Some studies suggest that tetracyclines, in combination with topical or intralesional steroids, are effective for cutaneous sarcoidosis.^{99,112,113} Immunomodulation rather than antimicrobial activity may be the mechanism of action behind the effectiveness of tetracyclines. In an open, non-randomized trial, complete resolution was achieved in eight and partial improvement in two of 12 patients treated with minocycline at a dose of 100 mg twice daily.¹¹³ Both nonresponders were African American and had cutaneous sarcoidosis for longer periods of time (54 and 72 months, respectively). Poor responses to tetracycline have been reported in cases of lupus pernio.^{99,114} It is possible that some of the cases in which tetracyclines were documented to be beneficial represented granulomatous rosacea or granulomatous papular dermatosis with noncaseating granulomas rather than cutaneous sarcoidosis.^{102,115} In one comparison study, the lesions in all 10 patients with granulomatous rosacea but none of the papular lesions in the three cases with known systemic sarcoidosis resolved during treatment with oxytetracycline.¹¹⁵ However, because tetracyclines have a relatively benign safety profile compared to other systemic therapies for sarcoidosis, these agents are frequently used. Therapeutic strategies include initiating treatment with minocycline as monotherapy for 3 months; if the response is unsatisfactory, hydroxychloroquine can be added. Alternatively, treatment can be started with both minocycline and hydroxychloroquine, plus topical or intralesional corticosteroids, with dose modifications depending on the clinical response. If the desired improvement is not achieved, low-dose methotrexate may be added to the regimen.

Because TNF- α is critical for the formation and maintenance of granulomas,¹¹⁶ medications that interfere with the production or actions of TNF- α are

promising therapeutic agents.⁷ Thalidomide was administered in an open-label trial to 15 therapeutically refractory patients with lupus pernio and systemic sarcoidosis in doses escalating from 50 to 200 mg daily.¹¹⁷ Lesional improvement was reported by 14 patients. In another case series, the biopsy specimens of eight patients treated with thalidomide revealed a reduction in the size of granulomas and in epidermal thickness.¹¹⁸ However, because of its teratogenic effects and high risk of peripheral neuropathy,¹¹⁹ other biologic anti-TNF inhibitors are being evaluated. Adalimumab has achieved favorable results after other treatments have failed. A woman with therapeutically refractory ulcerative cutaneous and systemic sarcoidosis responded to adalimumab in combination with prednisone, and another woman with extensive skin sarcoidosis significantly improved with the addition of adalimumab to the regimen of hydroxychloroquine and pentoxifylline.^{120,121} It has been our unsubstantiated opinion that a relatively high dose (40 mg/week) is usually required for treatment of cutaneous sarcoidosis. While case reports have shown a beneficial response to the anti-TNF- α antibody etanercept,^{122,123} others have indicated that infliximab and adalimumab are superior.^{124,125}

There are increasing data about the benefit of the chimeric monoclonal anti-TNF- α antibody infliximab in therapeutically recalcitrant systemic and cutaneous sarcoidosis.^{126,127} In a retrospective study, the lesions of 10 treatment unresponsive patients, including five with lupus pernio, decreased in size or resolved during infliximab therapy.¹²⁷ In an open-label, nonrandomized trial, three patients with extensive skin disease that failed treatment with systemic corticosteroids had marked responses to infliximab 3 mg/kg given at 0, 2, 4, 6, 10, and 14 weeks.¹²⁸ In two of the three cases, the lesions recurred after discontinuation of infliximab, requiring additional infusions.¹²⁸ In a randomized, placebo-controlled, double-blind study that included one of this review's authors, 138 patients with systemic sarcoidosis were treated with placebo or infliximab at doses of either 3 or 5 mg/kg at 0, 2, 6, 12, 18, and 24 weeks, and followed for 1 year.¹²⁹ Nineteen of these patients had lupus pernio and were randomly divided into three treatment groups.¹²⁹ There was significant improvement in the forced vital capacity. Although no statistically significant difference in the appearance of the facial lesions was evident in any group, this study was inadequately powered to evaluate this endpoint.¹²⁹ Significantly, post hoc exploratory analysis of the study suggested that infliximab therapy was most beneficial in the more severe cases.¹²⁹ A recent open-label Portuguese trial of infliximab in therapeutically

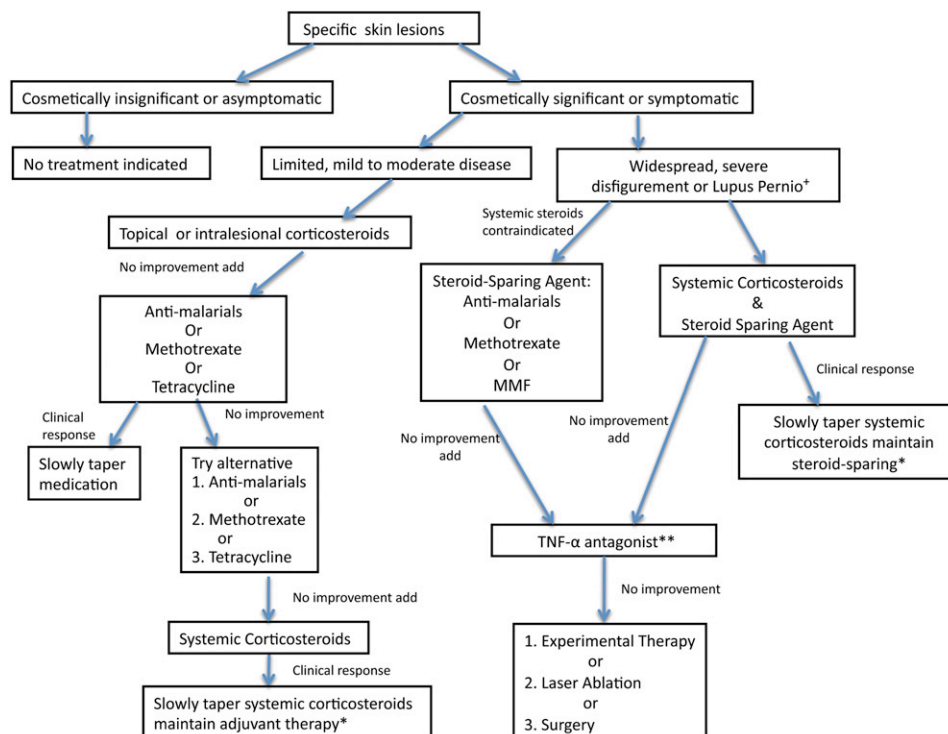


Fig 13. Proposed algorithm for treatment of specific cutaneous sarcoidosis based upon available literature and our clinical experience. Therapeutic regimens may be tailored according to individual patients. †Lupus pernio is notoriously challenging to treat, and some patients unresponsive to traditional combination therapy (steroids plus a steroid-sparing agent) have shown marked improvement with tumor necrosis factor- α (TNF- α) inhibitors. We believe it is appropriate to use TNF- α antagonists as a second-line treatment for steroid-resistant disfiguring lupus pernio. However, because the use of steroids and nonsteroidal agents are effective in some lupus pernio patients, insurance companies may require a trial with this traditional regimen before TNF- α antagonists are approved. *If unable to taper dose of corticosteroids to ≤ 15 mg every other day, switch to an alternative steroid-sparing agent. **We recommend infliximab or adalimumab as first line TNF- α antagonists. Concomitant low-dose methotrexate may be used to lessen the risk of antibody formation.

recalcitrant sarcoidosis found similar results; significant improvement or total resolution of the skin lesions occurred in all five patients with cutaneous disease.¹³⁰ Immunosuppressive therapy was reduced or discontinued in all patients, except for one with persistent hyperuricemia.¹³⁰ A retrospective study of 54 patients treated in a sarcoidosis clinic for lupus pernio found that drug regimens that contained infliximab (77%) were superior to corticosteroids plus noncorticosteroids (29%), corticosteroids alone (20%), and noncorticosteroids (11%) in achieving resolution, near resolution, or improvement of lesions.¹¹⁴ These results suggest that the therapeutic regimens that do not contain infliximab are less effective in the treatment of lupus pernio.¹¹⁴ Therefore, we recommend treatment with an anti-TNF- α antibody, such as infliximab, as the second-line therapy for corticosteroid-unresponsive lupus pernio.

Despite the promise of this class of agents, “sarcoidosis-like” granulomas have been reported in patients receiving these drugs for arthritis and other inflammatory conditions.¹³¹ While most granulomas involved the lungs, some cases developed skin lesions.^{131,132} Partial or complete regression occurs after discontinuation of TNF- α inhibitor therapy,¹³²⁻¹³⁴ but some patients have required corticosteroids for resolution.¹³⁵⁻¹³⁷

Mycophenolate mofetil at a dose of 30 to 45 mg/kg daily reportedly improved the skin lesions of five patients with cutaneous and systemic sarcoidosis refractory to other systemic therapies by 70% to 90% within 3 to 6 months, and facilitated prednisone tapering.¹³⁸ Other reports described the efficacy of mycophenolate mofetil in sarcoidosis uveitis,¹³⁹ neurosarcoidosis,¹⁴⁰ and renal sarcoidosis.¹⁴¹

Other therapeutic agents reported to improve cutaneous sarcoidosis include allopurinol,¹⁴²

isotretinoin,^{143,144} pentoxiphylline,¹⁴⁵ and melatonin.¹⁴⁶ Evidence supporting the efficacy of these medications is scant. Case studies have reported therapeutic benefit for psoralen plus ultraviolet A light phototherapy,^{147,148} photodynamic therapy,¹⁴⁹⁻¹⁵¹ pulsed-dye lasers,¹⁵² and CO₂ lasers.¹⁵³ The surgical resection of sarcoidal lesions is rarely performed. However, severely disfiguring lesions that are resistant to drug therapy may require reconstructive surgery or excision and flap closure.^{154,155}

A suggested therapeutic strategy for the treatment of cutaneous sarcoidosis based on available data and personal experience is included (Fig 13) although, as previously stated, supporting scientific evidence to guide the treatment of skin sarcoidosis is currently lacking.

SUMMARY

Although 134 years have passed since Hutchinson's initial publication of plaque sarcoidosis as "livid papillary psoriasis," the cause of sarcoidosis remains elusive. Advances in biomedical research techniques are facilitating the search for causative agents and the understanding of basic immune mechanisms responsible for the induction of non-caseating granulomas. Sarcoidosis may cause a diverse array of cutaneous manifestations. The reason for the unusual diversity of skin morphologies with relatively similar histopathologic appearance is not clear, but it may involve different etiologic agents, variable individual immune responses, and disparate genetic disposition. Evidence-based treatment of cutaneous sarcoidosis is hindered by a lack of large, randomized, controlled studies; practitioners are guided by results from uncontrolled experiments and evidence from opinions based on clinical experience, descriptive studies, and case reports. Corticosteroids remain the cornerstone of therapy, although other agents may be effective or corticosteroid-sparing. Patients with cutaneous sarcoidosis often have extracutaneous organ involvement, and therefore dermatologists must be aware of the disease's extracutaneous manifestations—this is the topic covered in part II of this review.

REFERENCES

- Brownell I, Ramirez-Valle F, Sanchez M, Prystowsky S. Evidence for mycobacteria in sarcoidosis. *Am J Respir Cell Mol Biol* 2011;45:899-905.
- Gupta D, Agarwal R, Aggarwal AN, Jindal SK. Molecular evidence for the role of mycobacteria in sarcoidosis: a meta-analysis. *Eur Respir J* 2007;30:508-16.
- Newman LS, Rose CS, Bresnitz EA, Rossman MD, Barnard J, Frederick M, et al. A case control etiologic study of sarcoidosis: environmental and occupational risk factors. *Am J Respir Crit Care Med* 2004;170:1324-30.
- Chen ES, Moller DR. Sarcoidosis—scientific progress and clinical challenges. *Nat Rev Rheumatol* 2011;7:457-67.
- Mana J, Marcoval J, Graells J, Salazar A, Peyri J, Pujol R. Cutaneous involvement in sarcoidosis. Relationship to systemic disease. *Arch Dermatol* 1997;133:882-8.
- English JC 3rd, Patel PJ, Greer KE. Sarcoidosis. *J Am Acad Dermatol* 2001;44:725-43.
- Lodha S, Sanchez M, Prystowsky S. Sarcoidosis of the skin: a review for the pulmonologist. *Chest* 2009;136:583-96.
- Costabel U, Guzman J, Baughman RP. Systemic evaluation of a potential cutaneous sarcoidosis patient. *Clin Dermatol* 2007;25:303-11.
- Baughman RP. Pulmonary sarcoidosis. *Clin Chest Med* 2004;25:521-30.
- Baughman RP, Teirstein AS, Judson MA, Rossman MD, Yeager H Jr, Bresnitz EA, et al. Clinical characteristics of patients in a case control study of sarcoidosis. *Am J Respir Crit Care Med* 2001;164(10 pt 1):1885-9.
- Hosoda Y, Sasagawa S, Yasuda N. Epidemiology of sarcoidosis: new frontiers to explore. *Curr Opin Pulm Med* 2002;8:424-8.
- Rybicki BA, Major M, Popovich J Jr, Maliarik MJ, Iannuzzi MC. Racial differences in sarcoidosis incidence: a 5-year study in a health maintenance organization. *Am J Epidemiol* 1997;145:234-41.
- Reich JM, Johnson RE. Incidence of clinically identified sarcoidosis in a northwest United States population. *Sarcoidosis Vasc Diffuse Lung Dis* 1996;13:173-7.
- Bresnitz EA, Strom BL. Epidemiology of sarcoidosis. *Epidemiol Rev* 1983;5:124-56.
- Pietinalho A, Hiraga Y, Hosoda Y, Lofroos AB, Yamaguchi M, Selroos O. The frequency of sarcoidosis in Finland and Hokkaido, Japan. A comparative epidemiological study. *Sarcoidosis* 1995;12:61-7.
- Cozier YC, Berman JS, Palmer JR, Boggs DA, Serlin DM, Rosenberg L. Sarcoidosis in black women in the United States: data from the Black Women's Health Study. *Chest* 2011;139:144-50.
- Hillerdal G, Nou E, Osterman K, Schmekel B. Sarcoidosis: epidemiology and prognosis. A 15-year European study. *Am Rev Respir Dis* 1984;130:29-32.
- Byg KE, Milman N, Hansen S. Sarcoidosis in Denmark 1980-1994. A registry-based incidence study comprising 5536 patients. *Sarcoidosis Vasc Diffuse Lung Dis* 2003;20:46-52.
- Morimoto T, Azuma A, Abe S, Usuki J, Kudoh S, Sugisaki K, et al. Epidemiology of sarcoidosis in Japan. *Eur Respir J* 2008;31:372-9.
- Iannuzzi MC, Rybicki BA, Teirstein AS. Sarcoidosis. *N Engl J Med* 2007;357:2153-65.
- Newman LS, Rose CS, Maier LA. Sarcoidosis. *N Engl J Med* 1997;336:1224-34.
- Lazarus A. Sarcoidosis: epidemiology, etiology, pathogenesis, and genetics. *Dis Mon* 2009;55:649-60.
- Sharma OP. Sarcoidosis around the world. *Clin Chest Med* 2008;29:357-63.
- Baughman RP, Lower EE, du Bois RM. Sarcoidosis. *Lancet* 2003;361:1111-8.
- Hunninghake GW, Costabel U, Ando M, Baughman R, Cordier JF, du Bois R, et al. ATS/ERS/WASOG statement on sarcoidosis. American Thoracic Society/European Respiratory Society/World Association of Sarcoidosis and other Granulomatous Disorders. *Sarcoidosis Vasc Diffuse Lung Dis* 1999;16:149-73.
- Chen ES, Moller DR. Etiology of sarcoidosis. *Clin Chest Med* 2008;29:365-77.

27. Zaba LC, Smith GP, Sanchez M, Prystowsky SD. Dendritic cells in the pathogenesis of sarcoidosis. *Am J Respir Cell Mol Biol* 2010;42:32-9.
28. Barnard J, Rose C, Newman L, Canner M, Martyny J, McCammon C, et al. Job and industry classifications associated with sarcoidosis in A Case-Control Etiologic Study of Sarcoidosis (ACCESS). *J Occup Environ Med* 2005;47:226-34.
29. Kreider ME, Christie JD, Thompson B, Newman L, Rose C, Barnard J, et al. Relationship of environmental exposures to the clinical phenotype of sarcoidosis. *Chest* 2005;128:207-15.
30. Kern DG, Neill MA, Wrenn DS, Varone JC. Investigation of a unique time-space cluster of sarcoidosis in firefighters. *Am Rev Respir Dis* 1993;148(4 pt 1):974-80.
31. Drake WP, Pei Z, Pride DT, Collins RD, Cover TL, Blaser MJ. Molecular analysis of sarcoidosis tissues for mycobacterium species DNA. *Emerg Infect Dis* 2002;8:1334-41.
32. Gazouli M, Ikononopoulos J, Trigidou R, Foteinou M, Kittas C, Gorgoulis V. Assessment of mycobacterial, propionibacterial, and human herpesvirus 8 DNA in tissues of greek patients with sarcoidosis. *J Clin Microbiol* 2002;40:3060-3.
33. Crowley LE, Herbert R, Moline JM, Wallenstein S, Shukla G, Schechter C, et al. "Sarcoid like" granulomatous pulmonary disease in World Trade Center disaster responders. *Am J Ind Med* 2011;54:175-84.
34. Agostini C, Adami F, Semenzato G. New pathogenetic insights into the sarcoid granuloma. *Curr Opin Rheumatol* 2000;12:71-6.
35. Rybicki BA, Walewski JL, Maliarik MJ, Kian H, Iannuzzi MC. The BTNL2 gene and sarcoidosis susceptibility in African Americans and whites. *Am J Hum Genet* 2005;77:491-9.
36. Smith G, Brownell I, Sanchez M, Prystowsky S. Advances in the genetics of sarcoidosis. *Clin Genet* 2008;73:401-12.
37. Rybicki BA, Iannuzzi MC, Frederick MM, Thompson BW, Rossman MD, Bresnitz EA, et al. Familial aggregation of sarcoidosis. A case-control etiologic study of sarcoidosis (ACCESS). *Am J Respir Crit Care Med* 2001;164:2085-91.
38. Design of a case control etiologic study of sarcoidosis (ACCESS). ACCESS Research Group. *J Clin Epidemiol* 1999; 52:1173-86.
39. Familial associations in sarcoidosis. A report to the Research Committee of the British Thoracic and Tuberculosis Association. *Tubercle* 1973;54:87-98.
40. Grunewald J, Brynedal B, Darlington P, Nisell M, Cederlund K, Hillert J, et al. Different HLA-DRB1 allele distributions in distinct clinical subgroups of sarcoidosis patients. *Respir Res* 2010;11:25.
41. Grunewald J. Review: role of genetics in susceptibility and outcome of sarcoidosis. *Semin Respir Crit Care Med* 2010;31: 380-9.
42. Judson MA. Sarcoidosis: lost in translation. *Respirology* 2011; 16:384-5.
43. Iannuzzi MC, Rybicki BA. Genetics of sarcoidosis: candidate genes and genome scans. *Proc Am Thorac Soc* 2007;4:108-16.
44. Schurmann M, Reichel P, Muller-Myhsok B, Schlaak M, Muller-Quernheim J, Schwinger E. Results from a genome-wide search for predisposing genes in sarcoidosis. *Am J Respir Crit Care Med* 2001;164:840-6.
45. Sanchez M, Prystowsky S. Sarcoidosis of the skin. In: Basow D, editor. *UpToDate*. Waltham (MA): UpToDate; 2010.
46. Elgart ML. Cutaneous sarcoidosis: definitions and types of lesions. *Clin Dermatol* 1986;4:35-45.
47. Marchell RM, Judson MA. Cutaneous sarcoidosis. *Semin Respir Crit Care Med* 2010;31:442-51.
48. Scadding JG, Mitchell DN, editors. *Sarcoidosis of the skin*. London: Chapman & Hall Medical; 1985. pp. 181-206.
49. Hanno R, Needelman A, Eiferman RA, Callen JP. Cutaneous sarcoidal granulomas and the development of systemic sarcoidosis. *Arch Dermatol* 1981;117:203-7.
50. Samtsov AV. Cutaneous sarcoidosis. *Int J Dermatol* 1992;31: 385-91.
51. Veien NK, Stahl D, Brodthagen H. Cutaneous sarcoidosis in Caucasians. *J Am Acad Dermatol* 1987;16(3 pt 1):534-40.
52. Yanardağ H, Pamuk ON, Karayel T. Cutaneous involvement in sarcoidosis: analysis of the features in 170 patients. *Respir Med* 2003;97:978-82.
53. Mahmoodi M, Ahmad A, Bansal C, Cusack CA. Palisaded neutrophilic and granulomatous dermatitis in association with sarcoidosis. *J Cutan Pathol* 2011;38:365-8.
54. James DG. Lupus pernio. *Lupus* 1992;1:129-31.
55. Jorizzo JL, Koufman JA, Thompson JN, White WL, Shar GG, Schreiner DJ. Sarcoidosis of the upper respiratory tract in patients with nasal rim lesions: a pilot study. *J Am Acad Dermatol* 1990;22:439-43.
56. Spiteri MA, Matthey F, Gordon T, Carstairs LS, James DG. Lupus pernio: a clinico-radiological study of thirty-five cases. *Br J Dermatol* 1985;112:315-22.
57. Paller AS, Surek C, Silva-Walsh I, Krespi Y, Freinkel RK. Cutaneous sarcoidosis associated with sarcoidosis of the upper airway. *Arch Dermatol* 1983;119:592-6.
58. Neville E, Mills RG, James DG. Sarcoidosis of the upper respiratory tract and its relation to lupus pernio. *Ann N Y Acad Sci* 1976;278:416-26.
59. Kerdel FA, Moschella SL. Sarcoidosis. An updated review. *J Am Acad Dermatol* 1984;11:1-19.
60. Young RJ 3rd, Gilson RT, Yanase D, Elston DM. Cutaneous sarcoidosis. *Int J Dermatol* 2001;40:249-53.
61. Dumitrescu SM, Schwartz RA, Baredes S, Whitworth JA, McDonald R, Zarbin M, et al. Mutilating facial sarcoidosis. *Dermatology* 1999;199:265-7.
62. Jacyk WK. Cutaneous sarcoidosis in black South Africans. *Int J Dermatol* 1999;38:841-5.
63. Sakemi H, Oiwa H. Psoriasiform plaques of sarcoidosis. *Intern Med* 2009;48:391.
64. Koch LH, Mahoney MH, Pariser RJ. Cutaneous sarcoidosis manifesting as extensive verrucous plaques. *Int J Dermatol* 2010;49:1458-9.
65. Streit M, Bohlen LM, Braathen LR. Ulcerative sarcoidosis successfully treated with apilgraf. *Dermatology* 2001;202: 367-70.
66. Yoo SS, Mimouni D, Nikolskaia OV, Kouba DJ, Sauder DN, Nousari CH. Clinicopathologic features of ulcerative-atrophic sarcoidosis. *Int J Dermatol* 2004;43:108-12.
67. Ichiki Y, Kitajima Y. Ulcerative sarcoidosis: case report and review of the Japanese literature. *Acta Derm Venereol* 2008; 88:526-8.
68. Albertini JG, Tyler W, Miller OF 3rd. Ulcerative sarcoidosis. Case report and review of the literature. *Arch Dermatol* 1997; 133:215-9.
69. Marchell RM, Judson MA. Chronic cutaneous lesions of sarcoidosis. *Clin Dermatol* 2007;25:295-302.
70. Krasowska D, Schwartz RA, Wojnowska D, Mackiewicz B, Czelej D. Polymorphous cutaneous and chronic multisystem sarcoidosis. *Acta Dermatovenerol Alp Panonica Adriat* 2008; 17:26-30.
71. Gregg PJ, Kantor GR, Telang GH, Lessin SR, Nowell PC, Vonderheid EC. Sarcoidal tissue reaction in Sézary syndrome. *J Am Acad Dermatol* 2000;43(2 pt 2):372-6.
72. Wong S, Pearce C, Markiewicz D, Sahota A. Seasonal cutaneous sarcoidosis: a photo-induced variant. *Photodermatol Photoimmunol Photomed* 2011;27:156-8.

73. Ahmed I, Harshad SR. Subcutaneous sarcoidosis: is it a specific subset of cutaneous sarcoidosis frequently associated with systemic disease? *J Am Acad Dermatol* 2006;54:55-60.
74. Vainsencher D, Winkelmann RK. Subcutaneous sarcoidosis. *Arch Dermatol* 1984;120:1028-31.
75. Koessler A, Grosshans E, Samain F, Runser C, Bernard F, Heid E. Tumoral sarcoidosis [in French]. *Ann Dermatol Venerol* 1995;122:783-5.
76. Antonovich DD, Callen JP. Development of sarcoidosis in cosmetic tattoos. *Arch Dermatol* 2005;141:869-72.
77. Chao SC, Yan JJ, Lee JY. Cutaneous sarcoidosis among Taiwanese. *J Formos Med Assoc* 2000;99:317-23.
78. James DG. Dermatological aspects of sarcoidosis. *Q J Med* 1959;28:108-24.
79. Chudomirova K, Velichkova L, Anavi B, Arnaudova M. Recurrent sarcoidosis in skin scars accompanying systemic sarcoidosis. *J Eur Acad Dermatol Venerol* 2003;17:360-1.
80. Sorabjee JS, Garje R. Reactivation of old scars: inevitably sarcoid. *Postgrad Med J* 2005;81:60-1.
81. Patel KB, Sharma OP. Nails in sarcoidosis: response to treatment. *Arch Dermatol* 1983;119:277-8.
82. Santoro F, Sloan SB. Nail dystrophy and bony involvement in chronic sarcoidosis. *J Am Acad Dermatol* 2009;60:1050-2.
83. Wakelin SH, James MP. Sarcoidosis: nail dystrophy without underlying bone changes. *Cutis* 1995;55:344-6.
84. Leibowitz MR, Essop AR, Schamroth CL, Blumsohn D, Smith EH. Sarcoid dactylitis in black South African patients. *Semin Arthritis Rheum* 1985;14:232-7.
85. Sam WM, Lynch PJ, editors. Principles and practice of dermatology. 2nd ed. New York: Churchill Livingstone; 1996. pp. 629-39.
86. Okamoto H, Mizuno K, Imamura S, Nagai S, Izumi T. Erythema nodosum-like eruption in sarcoidosis. *Clin Exp Dermatol* 1994;19:507-10.
87. Teirstein AS, Krumholtz S. Assessment of serum angiotensin-converting enzyme as a marker of activity in sarcoidosis: a study of 31 patients with erythema nodosum. *Mt Sinai J Med* 1987;54:144-6.
88. Neville E, Walker AN, James DG. Prognostic factors predicting the outcome of sarcoidosis: an analysis of 818 patients. *Q J Med* 1983;52:525-33.
89. Grunewald J, Eklund A. Löfgren's syndrome: human leukocyte antigen strongly influences the disease course. *Am J Respir Crit Care Med* 2009;179:307-12.
90. Paramothayan S, Lasserson T. Treatments for pulmonary sarcoidosis. *Respir Med* 2008;102:1-9.
91. White ES, Lynch JP 3rd. Current and emerging strategies for the management of sarcoidosis. *Expert Opin Pharmacother* 2007;8:1293-311.
92. Baughman RP, Lower EE, Kaufman AH. Ocular sarcoidosis. *Semin Respir Crit Care Med* 2010;31:452-62.
93. Kim JS, Judson MA, Donnino R, Gold M, Cooper LT Jr, Prystowsky EN, et al. Cardiac sarcoidosis. *Am Heart J* 2009;157:9-21.
94. Terushkin V, Stern BJ, Judson MA, Hagiwara M, Pramanik B, Sanchez M, et al. Neurosarcoidosis: presentations and management. *Neurologist* 2010;16:2-15.
95. Volden G. Successful treatment of chronic skin diseases with clobetasol propionate and a hydrocolloid occlusive dressing. *Acta Derm Venerol* 1992;72:69-71.
96. Khatri KA, Chotzen VA, Burrall BA. Lupus pernio: successful treatment with a potent topical corticosteroid. *Arch Dermatol* 1995;131:617-8.
97. Callen JP. Intralesional corticosteroids. *J Am Acad Dermatol* 1981;4:149-51.
98. Verbov J. The place of intralesional steroid therapy in dermatology. *Br J Dermatol* 1976;94(suppl 12):51-8.
99. Badgwell C, Rosen T. Cutaneous sarcoidosis therapy updated. *J Am Acad Dermatol* 2007;56:69-83.
100. Veien NK. Cutaneous sarcoidosis: prognosis and treatment. *Clin Dermatol* 1986;4:75-87.
101. Russo G, Millikan LE. Cutaneous sarcoidosis: diagnosis and treatment. *Compr Ther* 1994;20:418-21.
102. Doherty CB, Rosen T. Evidence-based therapy for cutaneous sarcoidosis. *Drugs* 2008;68:1361-83.
103. Schutt AC, Bullington WM, Judson MA. Pharmacotherapy for pulmonary sarcoidosis: a Delphi consensus study. *Respir Med* 2010;104:717-23.
104. Hawk A, English J. Cutaneous manifestations of sarcoidosis. In: Williams H, English 3rd J, Willions H, Bigby M, Diepgen T, Herxheimer A, et al, editors. Evidence-based dermatology. London: BMJ Books; 2003. pp. 659-72.
105. Siltzbach LE, Teirstein AS. Chloroquine therapy in 43 patients with intrathoracic and cutaneous sarcoidosis. *Acta Med Scand Suppl* 1964;425:302-8.
106. Zic JA, Horowitz DH, Arzubia C, King LE Jr. Treatment of cutaneous sarcoidosis with chloroquine. Review of the literature. *Arch Dermatol* 1991;127:1034-40.
107. Mosam A, Morar N. Recalcitrant cutaneous sarcoidosis: an evidence-based sequential approach. *J Dermatolog Treat* 2004;15:353-9.
108. Baughman RP, Lower EE. A clinical approach to the use of methotrexate for sarcoidosis. *Thorax* 1999;54:742-6.
109. Baughman RP, Lower EE. Evidence-based therapy for cutaneous sarcoidosis. *Clin Dermatol* 2007;25:334-40.
110. Veien NK, Brodthagen H. Cutaneous sarcoidosis treated with methotrexate. *Br J Dermatol* 1977;97:213-6.
111. Lower EE, Baughman RP. Prolonged use of methotrexate for sarcoidosis. *Arch Intern Med* 1995;155:846-51.
112. Marshall TG, Marshall FE. Sarcoidosis succumbs to antibiotics—implications for autoimmune disease. *Autoimmun Rev* 2004;3:295-300.
113. Bachelez H, Senet P, Cadranel J, Kaoukhov A, Dubertret L. The use of tetracyclines for the treatment of sarcoidosis. *Arch Dermatol* 2001;137:69-73.
114. Stagaki E, Mountford WK, Lackland DT, Judson MA. The treatment of lupus pernio: results of 116 treatment courses in 54 patients. *Chest* 2009;135:468-76.
115. Veien NK, Stahl D, Brodthagen H. Granulomatous rosacea treated with tetracycline. *Dermatologica* 1981;163:267-9.
116. Scallon B, Cai A, Solowski N, Rosenberg A, Song XY, Shealy D, et al. Binding and functional comparisons of two types of tumor necrosis factor antagonists. *J Pharmacol Exp Ther* 2002;301:418-26.
117. Baughman RP, Judson MA, Teirstein AS, Moller DR, Lower EE. Thalidomide for chronic sarcoidosis. *Chest* 2002;122:227-32.
118. Oliver SJ, Kikuchi T, Krueger JG, Kaplan G. Thalidomide induces granuloma differentiation in sarcoid skin lesions associated with disease improvement. *Clin Immunol* 2002;102:225-36.
119. Nguyen YT, Dupuy A, Cordoliani F, Vignon-Pennamen MD, Lebbe C, Morel P, et al. Treatment of cutaneous sarcoidosis with thalidomide. *J Am Acad Dermatol* 2004;50:235-41.
120. Heffernan MP, Smith DI. Adalimumab for treatment of cutaneous sarcoidosis. *Arch Dermatol* 2006;142:17-9.
121. Philips MA, Lynch J, Azmi FH. Ulcerative cutaneous sarcoidosis responding to adalimumab. *J Am Acad Dermatol* 2005;53:917.

122. Tuchinda C, Wong HK. Etanercept for chronic progressive cutaneous sarcoidosis. *J Drugs Dermatol* 2006;5:538-40.
123. Khanna D, Liebling MR, Louie JS. Etanercept ameliorates sarcoidosis arthritis and skin disease. *J Rheumatol* 2003;30:1864-7.
124. Field S, Regan AO, Sheahan K, Collins P. Recalcitrant cutaneous sarcoidosis responding to adalimumab but not to etanercept. *Clin Exp Dermatol* 2010;35:795-6.
125. Thielen AM, Barde C, Saurat JH, Laffitte E. Refractory chronic cutaneous sarcoidosis responsive to dose escalation of TNF-alpha antagonists. *Dermatology* 2009;219:59-62.
126. Baughman RP, Lower EE. Infliximab for refractory sarcoidosis. *Sarcoidosis Vasc Diffuse Lung Dis* 2001;18:70-4.
127. Doty JD, Mazur JE, Judson MA. Treatment of sarcoidosis with infliximab. *Chest* 2005;127:1064-71.
128. Saleh S, Ghodsian S, Yakimova V, Henderson J, Sharma OP. Effectiveness of infliximab in treating selected patients with sarcoidosis. *Respir Med* 2006;100:2053-9.
129. Baughman RP, Drent M, Kavuru M, Judson MA, Costabel U, du Bois R, et al. Infliximab therapy in patients with chronic sarcoidosis and pulmonary involvement. *Am J Respir Crit Care Med* 2006;174:795-802.
130. Aguiar M, Marcal N, Mendes AC, Bugalho de Almeida A. Infliximab for treating sarcoidosis patients, Portuguese experience. *Rev Port Pneumol* 2011;17:85-93.
131. Clementine RR, Lyman J, Zakem J, Mallepalli J, Lindsey S, Quinet R. Tumor necrosis factor-alpha antagonist-induced sarcoidosis. *J Clin Rheumatol* 2010;16:274-9.
132. Dhaille F, Viseux V, Caudron A, Dadban A, Tribout C, Boumier P, et al. Cutaneous sarcoidosis occurring during anti-TNF-alpha treatment: report of two cases. *Dermatology* 2010;220:234-7.
133. Toussiroit E, Pertuiset E, Kantelip B, Wendling D. Sarcoidosis occurring during anti-TNF-alpha treatment for inflammatory rheumatic diseases: report of two cases. *Clin Exp Rheumatol* 2008;26:471-5.
134. Josse S, Klemmer N, Moreno-Swirc S, Goeb V, Lequerre T, Vittecoq O. Infliximab induced skin and pulmonary sarcoidosis in a rheumatoid arthritis patient. *Joint Bone Spine* 2009;76:718-9.
135. Verschueren K, Van Essche E, Verschueren P, Taelman V, Westhovens R. Development of sarcoidosis in etanercept-treated rheumatoid arthritis patients. *Clin Rheumatol* 2007;26:1969-71.
136. O'Shea FD, Marras TK, Inman RD. Pulmonary sarcoidosis developing during infliximab therapy. *Arthritis Rheum* 2006;55:978-81.
137. Kerjoun M, Jouneau S, Lena H, Luraine R, Desrues B, Delaval P. Pulmonary sarcoidosis developing during treatment with etanercept [in French]. *Rev Mal Respir* 2011;28:360-4.
138. Kouba DJ, Mimouni D, Rencic A, Nousari HC. Mycophenolate mofetil may serve as a steroid-sparing agent for sarcoidosis. *Br J Dermatol* 2003;148:147-8.
139. Bhat P, Cervantes-Castaneda RA, Doctor PP, Anzaar F, Foster CS. Mycophenolate mofetil therapy for sarcoidosis-associated uveitis. *Ocul Immunol Inflamm* 2009;17:185-90.
140. Chaussebot A, Bourg V, Chanalet S, Fornari JM, Lebrun C. Neurosarcoidosis treated with mycophenolate mofetil: two cases [in French]. *Rev Neurol (Paris)* 2007;163:471-5.
141. Moudgil A, Przygodzki RM, Kher KK. Successful steroid-sparing treatment of renal limited sarcoidosis with mycophenolate mofetil. *Pediatr Nephrol* 2006;21:281-5.
142. Voelter-Mahlknecht S, Benez A, Metzger S, Fierlbeck G. Treatment of subcutaneous sarcoidosis with allopurinol. *Arch Dermatol* 1999;135:1560-1.
143. Georgiou S, Monastirli A, Pasmazi E, Tsambaos D. Cutaneous sarcoidosis: complete remission after oral isotretinoin therapy. *Acta Derm Venereol* 1998;78:457-9.
144. Chong WS, Tan HH, Tan SH. Cutaneous sarcoidosis in Asians: a report of 25 patients from Singapore. *Clin Exp Dermatol* 2005;30:120-4.
145. Zabel P, Entzian P, Dalhoff K, Schlaak M. Pentoxifylline in treatment of sarcoidosis. *Am J Respir Crit Care Med* 1997;155:1665-9.
146. Pignone AM, Rosso AD, Fiori G, Matucci-Cerinic M, Becucci A, Tempestini A, et al. Melatonin is a safe and effective treatment for chronic pulmonary and extrapulmonary sarcoidosis. *J Pineal Res* 2006;41:95-100.
147. Patterson JW, Fitzwater JE. Treatment of hypopigmented sarcoidosis with 8-methoxypsoralen and long wave ultraviolet light. *Int J Dermatol* 1982;21:476-80.
148. Graefe T, Konrad H, Barta U, Wollina U, Elsner P. Successful ultraviolet A1 treatment of cutaneous sarcoidosis. *Br J Dermatol* 2001;145:354-5.
149. Karrer S, Abels C, Wimmershoff MB, Landthaler M, Szeimies RM. Successful treatment of cutaneous sarcoidosis using topical photodynamic therapy. *Arch Dermatol* 2002;138:581-4.
150. Penrose C, Mercer SE, Shim-Chang H. Photodynamic therapy for the treatment of cutaneous sarcoidosis. *J Am Acad Dermatol* 2011;65:e12-4.
151. Patterson C. Successful treatment of cutaneous sarcoid by photodynamic therapy with minimal discomfort using a fractionated dosing regime. *Photodermatol Photoimmunol Photomed* 2009;25:276-7.
152. Goodman MM, Alpern K. Treatment of lupus pernio with the flashlamp pulsed dye laser. *Lasers Surg Med* 1992;12:549-51.
153. Young HS, Chalmers RJ, Griffiths CE, August PJ. CO₂ laser vaporization for disfiguring lupus pernio. *J Cosmet Laser Ther* 2002;4:87-90.
154. Gurkov R, Berghaus A. Nasal reconstruction in advanced sinunasal sarcoidosis. *Rhinology* 2009;47:327-9.
155. Smith R, Haeney J, Gulraiz Rauf K. Improving cosmesis of lupus pernio by excision and forehead flap reconstruction. *Clin Exp Dermatol* 2009;34:e25-7.
156. Spiteri MA, Taylor SJ. Retinoids in the treatment of cutaneous sarcoidosis. *Arch Dermatol* 1985;121:1486.
157. Tsuboi H, Yonemoto K, Katsuoka K. A 14-year-old girl with lichenoid sarcoidosis successfully treated with tacrolimus. *J Dermatol* 2006;33:344-8.
158. Seo SK, Yeum JS, Suh JC, Na GY. Lichenoid sarcoidosis in a 3-year-old girl. *Pediatr Dermatol* 2001;18:384-7.
159. Smith HR, Black MM. Verrucous cutaneous sarcoidosis. *Clin Exp Dermatol* 2000;25:98-9.
160. Cather JC, Cohen PR. Ichthyosiform sarcoidosis. *J Am Acad Dermatol* 1999;40(5 pt 2):862-5.
161. Mayock RL, Bertrand P, Morrison CE, Scott JH. Manifestations of sarcoidosis. Analysis of 145 patients, with a review of nine series selected from the literature. *Am J Med* 1963;35:67-89.
162. Wirth FA, Gould WM, Kauffman CL. Erythroderma in a patient with arthralgias, uveitis, and dyspnea. *Arch Dermatol* 1999;135:1411, 1414.
163. Katta R, Nelson B, Chen D, Roenigk H. Sarcoidosis of the scalp: a case series and review of the literature. *J Am Acad Dermatol* 2000;42:690-2.
164. Mann RJ, Allen BR. Nail dystrophy due to sarcoidosis. *Br J Dermatol* 1981;105:599-601.
165. Jones E, Callen JP. Hydroxychloroquine is effective therapy for control of cutaneous sarcoid granulomas. *J Am Acad Dermatol* 1990;23(3 pt 1):487-9.
166. Moss J, Zic J, Drake W. Mycobacterial infection masquerading as cutaneous sarcoidosis. *Clin Exp Dermatol* 2009;34:e199-201.

167. Lower EE, Baughman RP. The use of low dose methotrexate in refractory sarcoidosis. *Am J Med Sci* 1990;299:153-7.
168. Webster GF, Razi LK, Sanchez M, Shupack JL. Weekly low-dose methotrexate therapy for cutaneous sarcoidosis. *J Am Acad Dermatol* 1991;24:451-4.
169. Meyerle JH, Shorr A. The use of infliximab in cutaneous sarcoidosis. *J Drugs Dermatol* 2003;2:413-4.
170. Callejas-Rubio JL, Ortego-Centeno N, Lopez-Perez L, Benti-
cuaga MN. Treatment of therapy-resistant sarcoidosis with
adalimumab. *Clin Rheumatol* 2006;25:596-7.